

ARTIFICIAL ABORTION BY POTASSIUM CHLORIDE INJECTION FOR A PATIENT WITH CERVICAL STENOSIS AFTER CERVICAL CONIZATION

CHIAKI MARUYA¹⁾

YOSHIYA ANDO²⁾, KAZUHIRO KAKIMOTO²⁾ and YOSHINARI MATSUMOTO²⁾

1) *Department of Obstetrics and Gynecology, Ohyo Municipal Hospital*

2) *Department of Obstetrics and Gynecology, Wakayama Medical University, Kihoku Hospital*

Received May 28, 2003

Abstract: A patient who had cervical conization performed due to carcinoma in situ of uterine cervix performed wished to undergo an artificial abortion. However, cervical stenosis and deformation prevented the probe from passing through the cervical canal, and the external os was unclear. Assisted by transvaginal ultrasonic echo, we injected potassium chloride to the fetus. Most of contents of the uterus were exhausted by postoperative day 4. By transvaginal ultrasonic echo checked at postoperative day 9, no contents were recognized in the uterine cavity. The human chorionic gonadotropin level from a urinary test was ascertained as under 50 IU/l. There has been no sign of recurrence of the carcinoma for 5 years, indicating that this method is available when there are no other safer treatments, as in this case for example.

Key words : Artificial abortion, potassium chloride, conization

INTRODUCTION

Cervical conization is available for treatment of carcinoma in situ, and in some case for stage Ia1 cervical carcinoma of the uterine cervix¹⁾. After such an operation, scar stenosis is sometimes caused²⁾. It might cause dysmenorrhea, and prevent endometrial cytology, endometrial biopsy, and dilatation and curettage (D&C). We performed an artificial abortion by potassium chloride injection to the fetal heart assisted by transvaginal ultrasonic echo for a patient with scar stenosis due to a previous conization of the cervix.

CASE REPORT

The patient was a 35-year-old woman, gravida 3, para 0, with menarche at age 13, and a regular menstrual cycle. Six months previously she had a cervical conization performed for cervical carcinoma stage Ia₁. When she visited our clinic she was 5 weeks pregnant, and because of her social environment wished to undergo an artificial abortion.

She had dysmenorrhea, cervical stenosis and deformation after the conization, which prevented the probe from passing through the cervical canal. As well the external os was unclear, even under colposcopy. We abandoned D&C, and after informed consent was obtained, assisted by transvaginal ultrasonic echo, under venous anesthesia we used a 23

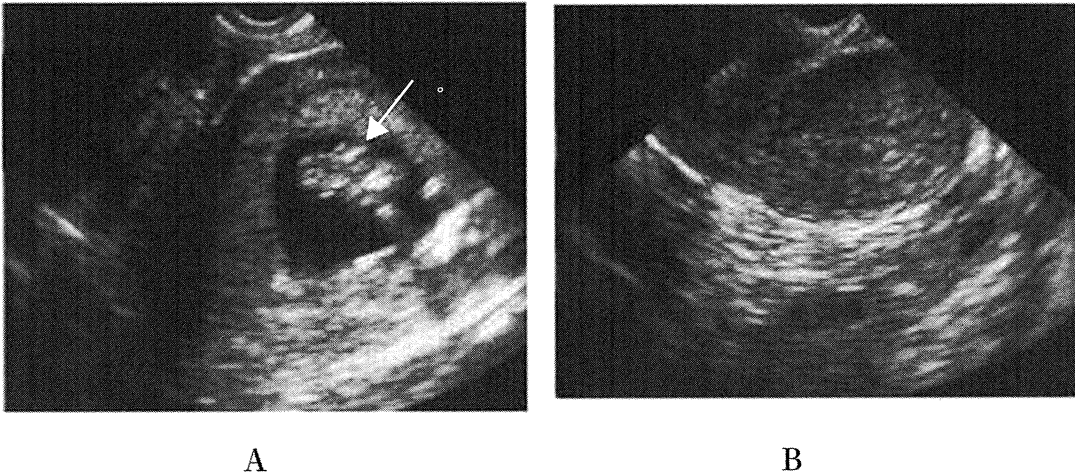


Fig. 1. (A), Trans vaginal ultrasonic echo when the potassium chloride was injected to the heart of the fetus with a 23 gauge liver biopsy needle assisted by trans vaginal ultrasonic echo at 9 weeks of pregnancy. White arrow: needle, (B), trans vaginal ultrasonic echo at postoperative day 9. Complete abortion was confirmed.

gauge liver biopsy needle to inject 0.3ml of 1M potassium chloride two times to the heart of the fetus at 9 weeks of pregnancy (Fig. 1A). The heartbeat of the fetus soon stopped. Most of contents of the uterus were exhausted by postoperative day 4, and a complete abortion was confirmed by transvaginal ultrasonic echo at postoperative day 9 (Fig. 1B). Her human chorionic gonadotropin level from a urinary test was under 50 IU/l at postoperative day 32. Her first postoperative menstrual bleeding started at day 50. The patient now has a regular menstrual cycle with no sign of recurrent of the cervical carcinoma 5 years after the conization.

CONCLUSION

Generally, dilatation and curettage (D&C), and administration of gemeprost are the preferred methods of artificial abortion during the early weeks. In this case, the external os was unclear and the patient had severe dysmenorrhea, so we concluded that the administration of gemeprost along with D&C was not appropriate.

Injection of potassium chloride is commonly used as a method of selective reduction. We had expected a missed abortion and the absorption of most of the uterine contents, but the operation succeeded in inducing a complete abortion. This method, while invasive for patients, is available when there are no other safer treatments, as in this case for example.

REFERENCES

- 1) Tseng, C. J., Horng, S. G., Soong, Y. K., Hsueh, S., Hsieh, C. H. and Lin, H. W. : Conservative conization for microinvasive carcinoma of the cervix. *Am. J. Obstet. Gynecol.* **176** : 1009-1010, 1997.
- 2) Larsson, G., Gullberg, B. and Grundsell, H. : A comparison of complications of laser and cold knife conization. *Obstet. Gynecol.* **62** : 213-217, 1983.
- 3) Herman, A., Maymon, R., Ron-el, R., Halperin, R., Ariely, S., Bukovsky, I. and Weinraub, Z. : Improved

techniques for first-trimester fetal reduction using simultaneous abdominal and transvaginal ultrasonographic guidance. Preliminary report. *Gynecol. Obstet. Invest.* **39** : 145-148, 1995.