

MALIGNANT ONCOCYTOMA OF THE PARANASAL SINUS

HIROSHI MARUYAMA¹, TAKAO MAKINO¹, YOSHIHIKO YOKOSE¹,
MASAHIRO TSUTSUMI¹, TOSHIAKI OKASAKA², YUKIKAZU HYO²,
TAKASHI MATSUNAGA² and YOICHI KONISHI^{1,a}

¹Department of Oncological Pathology, Cancer Center, Nara Medical University

²Department of Otorhinolaryngology, Nara Medical University, ^aTo whom offprint requests should be addressed

Received November 30, 1989

Summary : A case of malignant oncocytoma developing in the paranasal sinus of a 37-year-old Japanese man with a habit of heavy smoking is described. The primary tumor was found in the right maxillary sinus with local invasion to the nose and right ethmoidal sinus; it was composed of nests of large oncocytic cells, with finely granular and eosinophilic cytoplasm, nuclear pleomorphism and prominent nucleoli, surrounded by proliferation of spindle-shaped cells in some areas. Electron microscopically, the cytoplasm of oncocytic tumor cells was characterized by abundant mitochondria, and immunohistochemical investigation revealed positive binding for antibodies to S-100 protein and α_1 -antitrypsin, but a negative reaction for both cytokeratin and vimentin. At autopsy, metastatic nodules of tumor in the lungs, liver and pancreas independently exhibited both oncocytic cell- and sarcomatous cell compartments. This phenomenon is rare, and to the authors' knowledge, this would be histologically an unusual report of malignant oncocytoma with sarcomatous metastatic nodules arising from the paranasal sinus to be described in the literature.

Index Terms

malignant oncocytoma, sarcomatous component, paranasal sinus

INTRODUCTION

The characteristic histological feature of oncocytes¹⁾ is abundant granular eosinophilic cytoplasm which reflects tightly packed mitochondria demonstrated electron microscopically. An oncocytoma comprising such cells was first described for adenolymphoma by Jaffe²⁾ and subsequently oxyphilic granular cell adenoma of the parotid gland was used by Meza-cha vez³⁾. Since malignant oncocytoma (oxyphilic adenocarcinoma) of the parotid gland was first reported by Bauer and Bauer⁴⁾, rare malignant cases have been described in the salivary glands⁵⁾, palate⁶⁾, nasal cavity, paranasal sinus, kidney and thyroid gland⁷⁾, mediastinum⁸⁾ and lung⁹⁾. In the present paper, a case of malignant oncocytoma developing in the paranasal sinus is described in which some metastatic nodules were found to be composed of sarcomatoid area in addition to nests of oncocytes.

CASE REPORT

In February, 1982, a 37-year-old Japanese man was referred by a G. P. to the Department of Otorhinolaryngology in Nara Medical University Hospital with a four-month history of right nasal bleeding and obstruction, right buccal pain and subfever. On physical examination, a dark reddish mass was identified in the middle portion of the right nasal cavity along with hemorrhage. Ocular movement was normal, and the cervical lymph nodes were not palpable. Local X-ray examination revealed a

diffuse abnormal shadow in the right maxillary and right ethmoidal sinuses, and a defect on the lateral wall of the right maxillary sinus (Fig. 1). Horizontal computerized tomography (CT) also showed a defect on the lateral, anterior and inferior walls of the right maxillary sinus. Biopsy of the right nasal tumor was performed. The patient was treated with radiotherapy (Liniac, 6000 rad) and chemotherapy (cisplatin) via arterial infusion, and then underwent partial resection of the right maxillary sinus, which resulted in good local treatment.

The patient had smoked an average of 50 cigarettes per day for a period of 19 years. At admission, radiological and scintigraphical examinations did not reveal any abnormal shadows in the lungs, liver, pancreas, kidney and bone. Laboratory data showed that, although antistreptococcal antibody titer was higher (1 : 320 Todd) than normal, liver and renal functions were within normal values. Levels of the tumor markers, carcinoembryonic antigen (CEA) and α -fetoprotein were also within the normal range. Accordingly, because tumor mass was clinically not found in any other organs than the right nose and paranasal sinuses at admission, the patient was diagnosed as right maxillary sinus cancer at admission, the patient was diagnosed as right maxillary sinus cancer ($T_3N_0M_0$) with invasion to right nasal cavity.

Clinically, after the patient had been hospitalized for 4 months, he commenced suffering severe lumbar pain and gait disturbance caused by metastasis to the 9th thoracic vertebra and underwent orthopedical therapy. Thereafter, in spite of chemotherapy, tumor metastases in the lungs and liver developed and one year and ten months after his first visit to the hospital, death from respiratory failure occurred. Autopsy was performed about 3 hours after death.

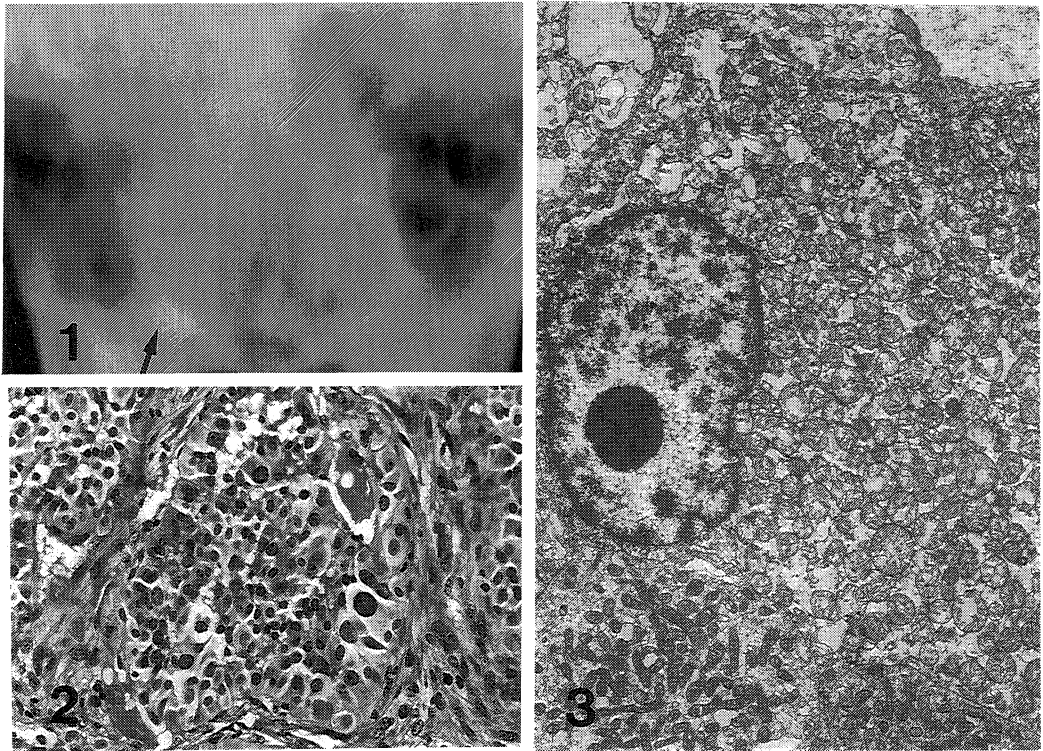
PATHOLOGIC FINDINGS

Surgical pathology

The original tumor taken from the right nasal cavity and maxillary sinus grossly appeared as small dark reddish necrotic masses and histologically exhibited trabecular or alveolar patterns separated by desmoplastic stroma (Fig. 2). Most of the tumor cells had features of oncocytes with nuclear pleomorphism i. e. they were large or polygonal with abundant, finely granular, eosinophilic cytoplasm and prominent nucleoli. Mitosis was frequently observed. Abundant dark blue-colored granules were evident after staining with phosphotungstic acid hematoxylin (PTAH). Electron microscopy revealed the cytoplasm of cells was predominantly packed with swollen mitochondria, of various shapes, ranging from elongated to spherical or oval (Fig. 3). Neither microvilli nor fat vacuoles were observed. Diagnosis of oncocytoma was based on these findings of surgical specimens.

Autopsy findings

On gross examination, the skin color appeared markedly icteric. Subcutaneous tissue of the right parietal region in the head showed a solid mass. The superficial lymph nodes were not enlarged. The right pleural cavity contained about 50 ml of bloody fluid and left first rib and sternum were swollen with a solid mass. The lungs had bilateral multiple various sized-nodules with the cut surface of the left lung showing a large tumor mass in the lower lobe. The eighth to twelfth thoracic vertebrae were also enlarged with masses. The liver was enlarged with a weight of 3800 g, and contained multiple tumor masses. The cut surfaces of metastases in the liver and lungs were well-defined, elastic hard and reddish white in color. The pancreatic head and tail were both enlarged with tumors in relation to the enlarged retroperitoneal lymph nodes. A few small metastatic lesions were also found in the kidneys,



- Fig. 1. Local X-ray view, showing a diffuse abnormal shadow in the right maxillary and right ethmoidal sinuses with a defect on the lateral wall of the right maxillary sinus.
- Fig. 2. Histology of the original tumor developing in the right maxillary sinus. Note tumor tissue comprising both oncocytic and spindle cell elements. (H. E., $\times 200$)
- Fig. 3. Electron microscopic view of the same tumor illustrated in fig. 2. The oncocytic cells are observed to be packed with abundant mitochondria. ($\times 5610$)

and only one small mass was observed in the spleen. Serosal wall of the urinary bladder had tumor invasion. The stomach demonstrated a round shaped and small ulcer and contained coffee-colored bloody fluid. The adrenals and thyroid glands were not affected.

Histopathologically, the metastatic tumor nodules observed in the lungs, liver and pancreas were of two types, individual nodules involving either oncocytes or spindle-shaped tumor cells (Fig. 4). Intermediate cells between large oncocytic tumor cells and spindle-shaped tumor cells were observed in the metastatic nodules of the lung (Fig. 5). A few metastatic nodules in the spleen and kidney were, however, all composed of spindle-shaped tumor cells without oncocytic cells. This latter type of nodule demonstrated the presence of abundant collagen fibers after Masson trichrome staining and many reticulin fibers arranged in fascicular patterns after reticulin staining. Metastatic bone tumors found in the 8th to 12th thoracic vertebrae expressed a mixed pattern, spindle-shaped cells being predominant but also were present oncocytic cells arranged in alveolar patterns. Oncocytic cells were negative after both periodic acid Schiff (PAS)-alcian blue (AB) double staining and the Sudan III

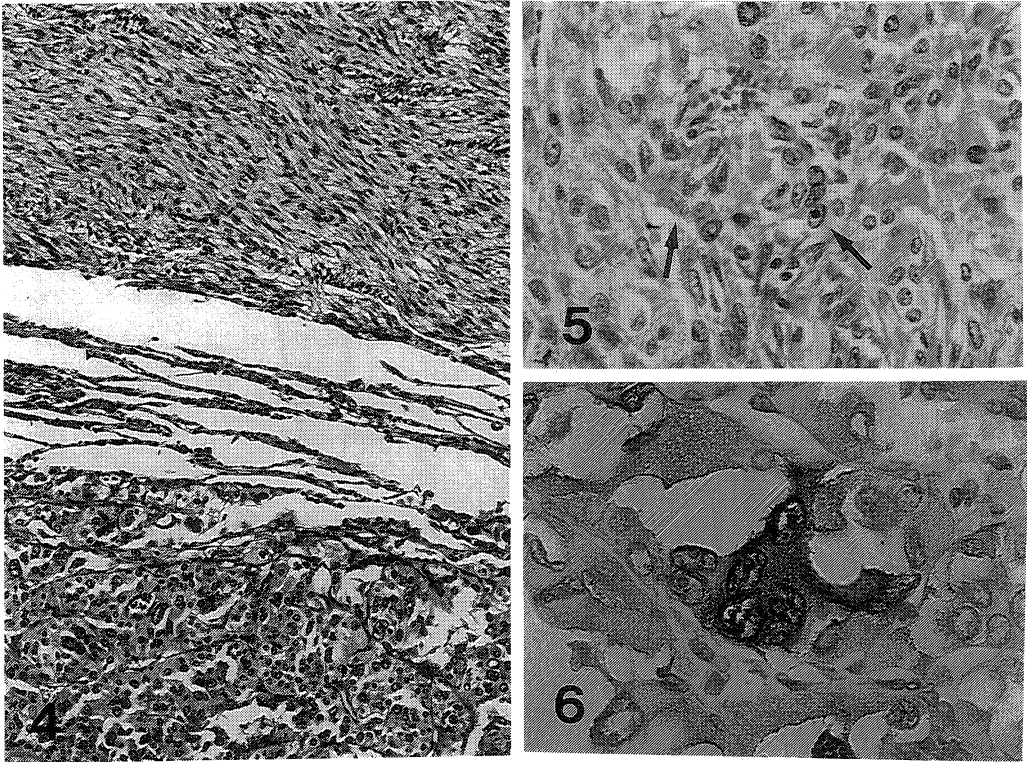


Fig. 4. Histology of a metastasis in the left lung, showing two types of nodules involving oncocytic and spindle tumor cells, independently. (H. E., $\times 100$)

Fig. 5. Histology of intermediate cells between oncocytic cells and spindle-shaped tumor cells in the metastasis of left lung. (H. E., $\times 200$)

Fig. 6. Positive staining of oncocytic tumor cells in a lung metastasis for S-100 protein. (Peroxidase antiperoxidase stain, $\times 400$)

(lipid) reaction.

Immunohistochemically, the oncocytic tumor cells were positive for binding of antibodies to S-100 protein (1 : 100, Dako Corporation, Denmark, Fig. 6) and α_1 -antitrypsin (1 : 400, Dako), but negative for cytokeratin (1 : 200, Dako) and vimentin (1 : 200, Dako). Furthermore, the spindle-shaped tumor cells in metastasis of the lung were negative for S-100 protein, cytokeratin, vimentin and desmin (1 : 10, Dako), and some of them were positive for α_1 -antitrypsin.

DISCUSSION

Since the first report of Hamperl⁷⁾, malignant oncocytomas arising in the nose and paranasal sinuses are very rare and the case presented in this report is, to the authors' knowledge, only the eighth description in the literature (Table 1). In earlier reports, the ages of the patients were all in excess of 50 years. However, our patient was only 37 years old, much younger than those cases.

It has been understood that oncocytes may be best considered as somatic mutants, and that oncocytic

Table 1. Reported cases of malignant oncocytoma arising in the nose and paranasal sinuses

Case No.	Age	Sex	Site	Extent of invasion	Confirmed by other techniques	Author
1	73	M	nasal	lymphnode and parotis	none	Hamperl (1962) ⁷⁾
2	55	M	nasal	paranasal sinuses and orbit	none	Hamperl (1962) ⁷⁾
3	61	M	nasal	maxillary sinus	histochemistry ^a	Cohen and Batsakis ¹⁰⁾ (1968)
4	61	M	nasal	orbit and malar bone	histochemistry and electron microscopy	Johns ¹¹⁾ (1976)
5	64	M	maxillary sinus	local invasion to surrounding tissue	none	Handler and Ward ¹²⁾ (1979)
6	50	M	nasal	local recurrence in the nasal cavity	none	Mahmound (1979) ¹³⁾
7	60	F	ethmoid sinus	orbit and nasal cavity	electron microscopy	Chui (1985) ¹⁴⁾
8	37	M	maxillary sinus	nasal cavity and ethmoidal sinus	histochemistry and electron microscopy	Maruyama (1989)

^aHistochemical confirmation by phosphotungstic acid hematoxylin (PTAH) staining.

transformation of epithelial cells should be regarded as a re-differentiation¹⁵⁾. However, Batsakis (1979)¹⁵⁾ has further maintained that solid oncocytomas originating in seromucous glands or epithelia such as those of the nose and paranasal sinuses possess a locally aggressive nature. Our case also showed distant metastasis mainly to the lungs, liver, bone and soft tissue and retroperitoneal lymphnodes with a few metastases to the pancreas, kidneys and spleen. Johns, M. E. et al. (1976)¹¹⁾ have pointed out that under electron microscopy two types of oncocyte may be present in the salivary gland, that is, an epithelial oncocyte and a myoepithelial oncocyte, the latter having a cytoplasm rich in fibers. In the present case, it is notable that the sarcomatous component of the malignant oncocytoma might be confirmed by examination of metastatic nodules of lung and liver. This feature of dual oncocytoma and sarcomatoid component is reminiscent of the concept of carcinosarcoma. Although the sarcomatoid component in the present case histologically demonstrated features suggesting the possibility of fibrosarcoma, such spindle-shaped tumor cells were immunohistochemically demonstrated positive reactivity to α_1 -antitrypsin. It has been suggested that sarcoma-like areas are derived from carcinoma cells in some cases and may be partly a neoplastic stromal response in others¹⁵⁾. Therefore, the finding of metastatic nodules comprising only spindle-shaped cells might indicate the former possibility in the present case.

The oncocytic tumor cells were immunohistochemically positive for antibodies to S-100 protein and α_1 -antitrypsin but negative for binding of anti-cytokeratin antibody. This is in line with the fact that whereas epithelial malignancies are usually positive for keratin, oncocytes of a renal oncocytoma proved positive for α_1 -antitrypsin and negative for cytokeation in an earlier investigation of immunohistochemical expression¹⁶⁾. It has recently been reported that the α -chain of S-100 protein is present in normal epithelium of salivary glands¹⁷⁾. Accordingly, the immunohistochemical results concerning the present case suggest that the oncocytic tumor cells might be derived from seromucous glands or intercalated ducts in the epithelium of the paranasal sinus.

A malignant oncocytoma with a sarcomatous component reported here might give us useful information the biologic and pathologic characters of oncocytoma in the nose and paranasal sinus.

ACKNOWLEDGEMENTS

The authors deeply appreciate the assistance of Dr. Malcolm A. Moore and Mrs. Hiroko Megumi in the preparation of this manuscript. The skillfull technical assistance by Mrs. Yohko Okuno is also acknowledged.

REFERENCES

- 1) **Hamperl, H.** : Beiträge zur normalen und pathologischen Histologie menschlicher Speicheldrüsen. *Zeitschrift für Mikroskopisch-anatomisch Forschung* **27** : 1-55, 1931.
- 2) **Jaffé, R. H.** : Adenolymphoma (oncocytoma) of parotid gland. *Am. J. Cancer* **16** : 1415-1423, 1932.
- 3) **Meza-chávez, L.** : Oxyphilic granular cell adenoma of the parotid gland (oncocytoma) ; Report of five cases and study of oxyphilic granular cells (oncocytes) in normal parotid glands. *Am. J. Pathol.* **25** : 523-528, 1949.
- 4) **Bauer, W. A. and Bauer, J. D.** : Classification of glandular tumors of salivary gland—Study of one hundred forty-three cases. *AMA Arch. Pathol.* **55** : 328-346, 1953.
- 5) **Gray, S. R., Cornog, J. L. and Seo, I. S.** : Oncocytic neoplasms of salivary glands. A report of fifteen cases including two malignant oncocytoma. *Cancer* **38** : 1306-1317, 1976.
- 6) **Briggs, J. and Evans, J. N. G.** : Malignant oxyphilic granular cell tumor (oncocytoma) of the palate. *Oral. Surg.* **23** : 796-802, 1967.
- 7) **Hamperl, H.** : Benign and malignant oncocytoma. *Cancer* **15** : 1019-1027, 1962.
- 8) **Meijer, S. and Hoitsma, H. F. W.** : Malignant intra-thoracic oncocytoma. *Cancer* **49** : 97-100, 1982.
- 9) **Nielsen, A. L.** : Malignant bronchial oncocytoma. Case report and review of the Literature. *Hum. Pathol.* **16** : 852-854, 1985.
- 10) **Cohen, M. A. and Batsakis, J. G.** : Oncocytic neoplasms of salivary glands. An untrastmatural study. *Laryngoscope* **87** : 862-871, 1976.
- 12) **Handler, S. D. and Ward, P. H.** : Oncocytoma of the maxillary sinus. *Laryngoscope* **89** : 327-376, 1979.
- 13) **Mahmoud, M. D.** : Malignant oncocytoma of the nasal cavity. *J. Laryngol. Otol.* **93** : 729-734, 1979.
- 14) **Chui, R. T. K., Liao, S-Y and Bosworth, H.** : Recurrent oncocytoma of the ethmoid sinus with orbital invasion. *Otolaryngol. Head & Neck Surg.* **93** : 267-270, 1985.
- 15) **Batsakis, J. G.** : Tumors of the major salivary glands. *in* Tumors of the Head and Neck, Clinical and Pathological Considerations (Batsakis, J. G., ed.). Williams and Willkins Co., Baltimore, 1979.
- 16) **Holthöfer, H.** : Renal oncocytoma : immuno- and carbohydrate histochemical characterization. *Virchows Arch. A.* **410** : 509-513, 1987.
- 17) **Haimoto, H., Hosoda, S. and Kato, K.** : Differential distribution of immunoreactive S100- α and S100- β proteins in normal nonnervous human tissues. *Lab. Invest.* **57** : 489-498, 1987.