

POSITION OF AXIS FOR ROTATION AT THE INTERVERTEBRAL JOINT IN RATS

YOSHIYUKI TOHNO, SETSUKO TOHNO,
CHO AZUMA and YUMI MORIWAKE
Department of Anatomy, Nara Medical University

TSUKASA KUMAI
Department of Orthopedic Surgery, Nara Medical University

Received June 2, 2004

Abstract : To elucidate whether the position of axis for rotation at the intervertebral joint is related to the spinal curvature, the authors investigated the spinal columns of rats. The spinal column of the rat was composed of 7 cervical, 13 thoracic, 6 lumbar, 4 sacral, and 27 coccygeal vertebrae. It was observed that the position of axis for rotation at the intervertebral joint was shifted on the superior and inferior views of the 2nd thoracic vertebra and was next shifted on the superior and inferior views of the 10th thoracic vertebra. X-ray examination demonstrated that lordosis was seen in the cervical and lower lumbar (L4-L6) spine, whereas kyphosis was seen in the thoracic and upper lumbar (L1-L3) spine. The present study did not support the possibility that the position of axis for rotation at the intervertebral joint was dorsal in the spinal site of lordosis, whereas it was ventral in the spinal site of kyphosis.

Key words : Intervertebral joint, spine, vertebra, rat

INTRODUCTION

It is well known that kyphosis and lordosis are present in the spine. In the crab-eating monkey, the position of axis for rotation at the intervertebral joint is shifted from ventral to dorsal position on the superior and inferior views of the 10th thoracic vertebra¹⁾. It is ambiguous whether the position of axis for rotation at the intervertebral joint is related to the spinal curvature. The authors^{2,3)} previously investigated the relationships between spinal curvature and position of axis for rotation at the intervertebral joint in spines of a baboon and Japanese monkeys and found that there were no clear relationships. Therefore, the authors re-investigated the relationship between spinal curvature and position of axis for rotation at the intervertebral joint using rat spine.

MATERIALS AND METHODS

Materials

The animal experiment was carried out in accordance with the US Guide for the care and use of laboratory animals. Wistar rats (Nihon Clea Co., Osaka, Japan) were sacrificed with

ethyl ether. The spinal columns were resected and photographed by a soft X-ray apparatus. Thereafter, the vertebrae were isolated from the spinal columns.

X-Ray Examination

Spinal columns were photographed with a soft X-ray apparatus (Softex type E40; Softex Co., Osaka, Japan) as described previously⁴⁾.

Photograph of Vertebrae

Vertebrae were photographed with a digital camera (FinePix S602; Fuji Film Co., Japan).

RESULTS

Structure of Vertebrae

Wistar rats of about one year old were used in the present study. The spinal column consisted of 7 cervical, 13 thoracic, 6 lumbar, 4 sacral, and 27 coccygeal vertebrae (Table 1).

Table 1. Vertebrae of Human, Baboon, Japanese Monkey, and Rat

Species	Number of Vertebra			
	Cervical	Thoracic	Lumbar	Sacral
Japanese	7	12	5	5
Baboon	7	12	7	3
Japanese Monkey	7	12	7	3
Rat	7	13	6	4

Figure 1 shows the lower thoracic (T8-T13) and lumbar vertebrae. The slender accessory process was present in the range between the 11th thoracic and 3rd lumbar vertebrae. The accessory process was short in the 4th lumbar vertebra and was absent from the 5th and 6th lumbar vertebrae. The superior articular processes were tightly held between the accessory and inferior articular processes of the adjacent vertebra in the range between the 12th thoracic and 4th lumbar vertebrae (Fig. 2). Therefore, the rotation movement of the spinal column was considerably restricted in the range between the 12th thoracic and 4th lumbar vertebrae.

Rotation Movement at the Intervertebral Joint

The position of axis for rotation at the intervertebral joint was examined in the cervical, thoracic, and lumbar vertebrae of two rats. Figure 3 indicates that the position of axis for rotation at the intervertebral joint is shifted from dorsal to ventral direction on the superior and inferior views of the 2nd thoracic vertebra in the rat. The position of axis for rotation at the intervertebral joint was dorsal in the 2nd-7th cervical and 1st thoracic vertebrae, whereas it was ventral in the thoracic vertebrae caudal to the 3rd thoracic vertebra.

Figure 4 indicates that the position of axis for rotation at the intervertebral joint is shifted from ventral to dorsal direction on the superior and inferior views of the 10th thoracic vertebra in the rat. The position of axis for rotation was ventral in the thoracic vertebrae cranial to the 10th thoracic vertebra, whereas it was dorsal in the 11th-13th thoracic vertebrae and all of the lumbar vertebrae.

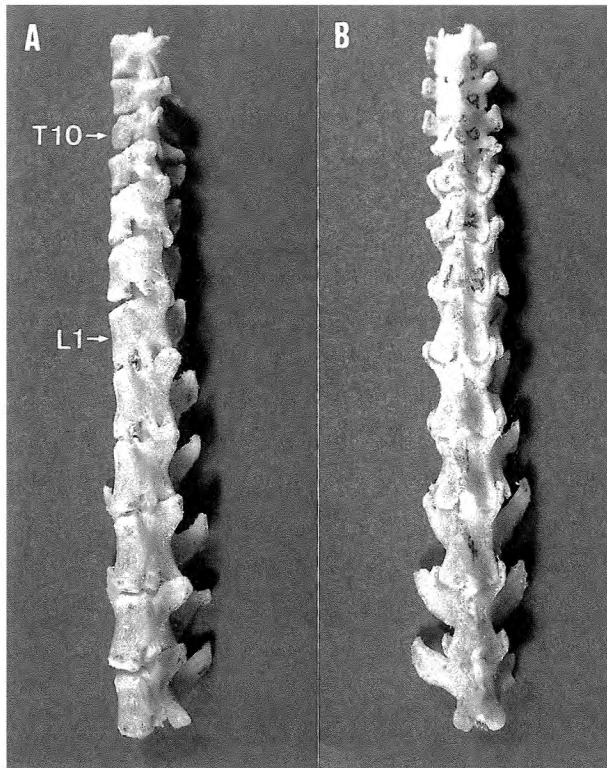


Fig. 1. Lateral (A) and posterior (B) views of the lower (T8-T13) thoracic and lumbar vertebrae in rat. T10 and L1 indicate the 10th thoracic and the 1st lumbar vertebrae, respectively.




Fig. 2. Lateral view of the 1st and 2nd lumbar vertebrae in rat. A, I, and S denote the accessory, inferior articular, and superior articular processes, respectively.

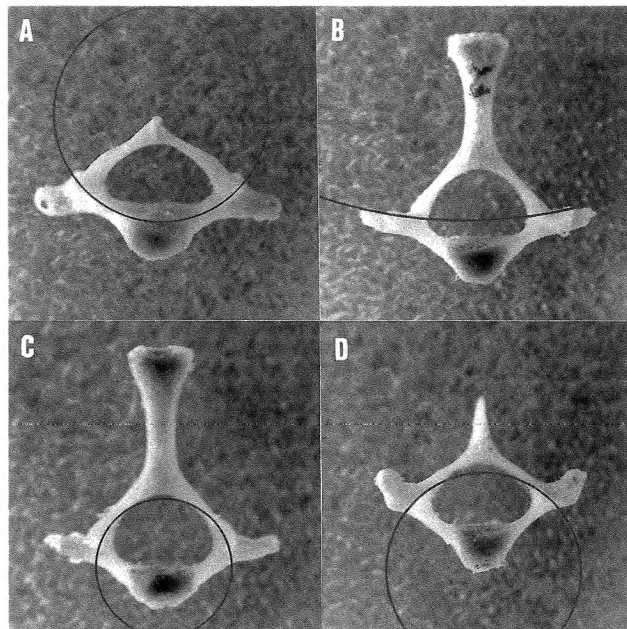


Fig. 3. The upper shift of the position of axis for rotation at the intervertebral joint from dorsal to ventral direction. The circles show the rotation movement at the intervertebral joint. A, inferior view of the 1st thoracic vertebra; B, superior view of the 2nd thoracic vertebra; C, inferior view of the 2nd thoracic vertebra; and D, superior view of the 3rd thoracic vertebra.

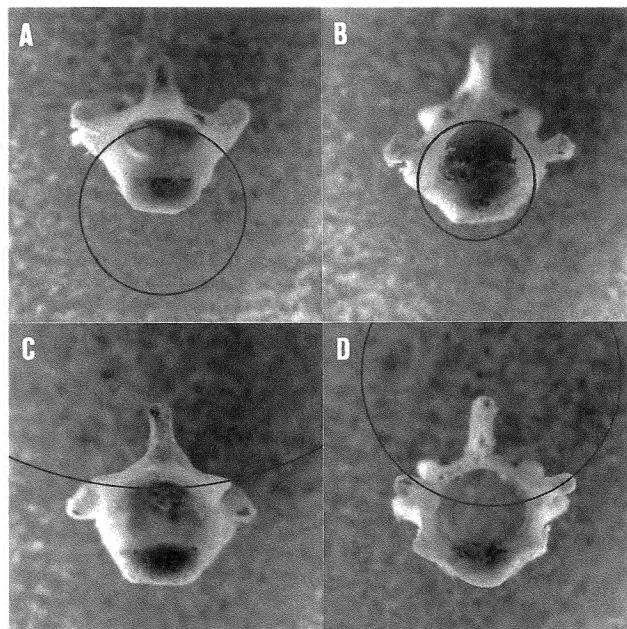


Fig. 4. The lower shift of the position of axis for rotation at the intervertebral joint from ventral to dorsal direction. The circles show the rotation movement at the intervertebral joint. A, inferior view of the 9th thoracic vertebra; B, superior view of the 10th thoracic vertebra; C, inferior view of the 10th thoracic vertebra; and D, superior view of the 11th thoracic vertebra.

The shift of axial position for rotation at the intervertebral joint occurs suddenly on the superior and inferior views of both the 2nd and 10th thoracic vertebrae, but does not occur gradually.

Relationship Between the Position of Axis for Rotation at the Intervertebral Joint and Curvature of Spinal Column

To examine the relationship between the position of axis for rotation at the intervertebral joint and the curvature of the spinal column, the spinal columns were photographed beforehand with a soft X-ray apparatus, and thereafter the vertebrae were isolated from the spinal columns. Figure 5 shows an X-ray photograph of the rat spinal column. Lordosis was seen in both the cervical and the lower lumbar (L4-L6) spine, whereas kyphosis was seen in the thoracic and upper lumbar (L1-L3) spine. Therefore, the possibility that the position of axis for rotation at the intervertebral joint is dorsal in the spinal site of lordosis, whereas it is ventral in the spinal site of kyphosis, was not supported by the present study.

DISCUSSION

The present study revealed that the position of axis for rotation at the intervertebral joint was shifted from dorsal to ventral direction on the superior and inferior views of the 2nd thoracic vertebra and was next shifted from ventral to dorsal direction on the superior and inferior views of the 10th thoracic vertebra in the rat.

Kimura et al.¹⁾ reported that in the crab-eating monkey, the position of axis for rotation at the intervertebral joint was shifted from ventral to dorsal direction on the superior and inferior views of the 10th thoracic vertebra. The authors^{2,3)} previously investigated the spinal columns of a baboon and Japanese monkeys and observed that the position of axis for rotation at the intervertebral joint in the baboon and Japanese monkeys was shifted from dorsal to ventral direction on the superior and inferior views of the 1st thoracic vertebra and was next shifted from ventral to dorsal direction on the superior and inferior views of the 10th thoracic vertebra, with some exceptions in the Japanese monkeys. In the case of Japanese³⁾, the position of axis for rotation at the intervertebral joint was shifted from dorsal to ventral direction on the superior and inferior views of the 1st thoracic vertebra and was next shifted from ventral to dorsal direction on the superior and inferior views of the 12th thoracic vertebra, with some exceptions.

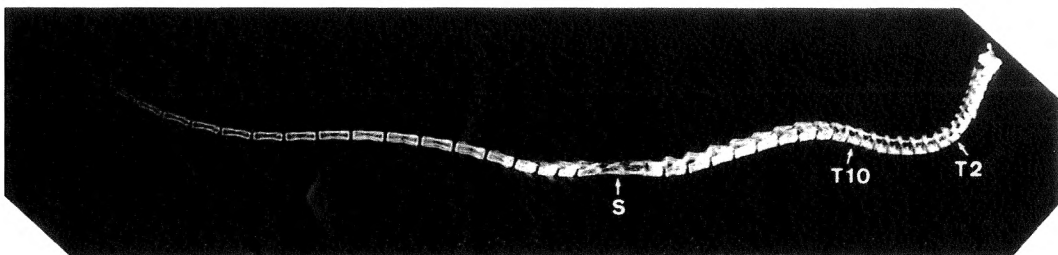


Fig. 5. X-ray photograph of the spinal column in rat. T2, T10, and S indicate the 2nd thoracic, 10th thoracic vertebrae, and sacrum, respectively.

The possibility that the position of axis for rotation at the intervertebral joint is dorsal in the spinal site of lordosis, whereas it is ventral in the spinal site of kyphosis, was not supported by the present study. The upper shift of the position of axis for rotation at the intervertebral joint occurs at the 1st thoracic vertebra in the Japanese, baboon, and Japanese monkey, whereas it occurs at the 2nd thoracic vertebra in the rat. The thoracic vertebrae were composed of 12 in the Japanese, baboon, and Japanese monkey, whereas they were composed of 13 in the rat (Table 1). The lower shift of the position of axis for rotation at the intervertebral joint occurred at the 10th thoracic vertebra in the baboon, Japanese monkey, and rat, whereas it occurred at the 12th thoracic vertebra in the Japanese. It is unlikely that the lower shift of the position of axis at the intervertebral joint is related to number of the thoracic vertebra.

REFERENCES

- 1) Kimura, K., Konishi, M., Takahashi, Y. and Iwamoto, S.: The skeletal system of *Macaca Fascicularis*—Description and measurement. Part III. The vertebrae. *J. Natl. Def. Med. Coll.* 11 : 19–34, 1986.
- 2) Tohno, Y., Tohno, S., Furuta, K., Morimoto, M., Moriwake, Y., Azuma, C., Yamada, M.-o. and Hayashi, M.: Structure and bone mineral density of baboon vertebrae. *J. Nara Med. Assoc.* 54 : 247–255, 2003.
- 3) Tohno, Y., Tohno, S., Furuta, K., Azuma, C., Itami, Y., Koizumi, K., Saikawa, S., Satoh, S., Zuo, S., Takamura, Y., Moriwake, Y. and Hayashi, M.: Axis for rotation at the intervertebral joint in Japanese monkeys. *J. Nara Med. Assoc.* 55 : 43–50, 2004.
- 4) Tohno, Y., Tohno, S., Matsumoto, H. and Naito, K.: A trial of introducing soft X-ray apparatus into dissection practice for students. *J. Nara Med. Assoc.* 36 : 365–370, 1985.