

# **Ocular Blood Flow, Before, During, and After Vitrectomy**

## **Determined by Laser Speckle Flowgraphy**

Masahiro Okamoto, MD, Toyooki Matsuura, MD, PhD, Nahoko Ogata, MD, PhD,

Department of Ophthalmology, Nara Medical University, Kashihara, Nara, Japan

**Short title:** Ocular Blood Flow, Before, During, and After Vitrectomy

Article: original article

1. All author's affiliation: Department of Ophthalmology, Nara Medical University,

Nara, Japan

2. **Commercial Relationship:** None

No financial support.

3. This study was performed with informed consent.

**Key Words:** Laser speckle flowgraphy, Ocular blood flow, Vitreous surgery,

Intraocular pressure

**Correspondence:** Masahiro Okamoto, M.D

Department of Ophthalmology, Nara Medical University

Shijo-cho 840, Kashihara, Nara 634-8522, Japan.

Phone: +81-744-29-8884

Fax: +81-744-23-8032

e-mail: [okamot626@naramed-u.ac.jp](mailto:okamot626@naramed-u.ac.jp)

## **Abstract**

**Purpose:** Vitrectomy markedly alters the intraocular milieu which can then affect the physiology of the retina and choroid. The alterations should also affect the ocular blood flow, but the results of studies on this have been contradictory. Thus, the purpose of this study was to determine whether vitrectomy alters the ocular blood flow as determined by laser speckle flowgraphy (LSFG).

**Methods:** Twenty eyes of 20 patients that underwent vitrectomy for an idiopathic macular hole or an epiretinal membrane were studied. Microincision vitreous surgery was performed with a standard 23-gauge system. The ocular blood flow of the optic nerve head, retinal vessels, and choroid were determined by LSGF before the vitrectomy, during the vitrectomy, and 2 weeks and 1 month after the vitrectomy.

**Results:** After the vitrectomy, the blood flow of the optic nerve head, retinal vessels, and choroid did not differ significantly from that before the vitrectomy. During the vitrectomy the blood flow of the optic nerve head and retinal vessels decreased significantly from the baseline with increasing infusion pressure from 20 mmHg to 40 mm Hg ( $P < 0.01$ ), and the choroidal blood flow decreased significantly when the infusion pressure increased from 8 mmHg to 20 mmHg and from 20 mmHg to 40 mmHg ( $P < 0.01$ ,  $P < 0.01$ , respectively).

**Conclusions:** The blood flow did not differ significantly postoperatively from that of

before the vitrectomy but it was significantly reduced during the vitrectomy with increasing infusion pressure. Careful attention should be paid on the infusion pressures during the vitrectomy.

## Introduction

Vitreotomy replaces the vitreous with saline or aqueous humor of low viscosity, and the partial pressure of oxygen in the vitrectomized eye rises because of an increase in convection and higher solubility of oxygen in the replacement fluids.<sup>1</sup> The ocular blood flow is known to play a role in increasing the oxygen pressure in the vitreous, however the effects of vitrectomy on the ocular blood flow is still contradictory.

The ocular blood flow can be determined by scanning laser ophthalmoscopy, laser speckle flowgraphy (LSFG), Heidelberg retinal flowmetry, and color Doppler imaging. Previously, the effects of the vitrectomy on the ocular blood flow were investigated only in eyes with diabetic retinopathy and diabetic macular edema but the results are contradictory probably because the measuring methods, instruments, regions measured, and disease processes were different.<sup>2-6</sup>

LSFG can determine the blood flow velocity in ocular tissues including the retinal and choroidal vessels without the administration of contrast agents.<sup>7</sup> In addition, LSFG can be performed in the same areas automatically once the topographic features of the retinal vasculature are memorized by the software of the instrument. The reproducibility of blood flow velocity measurements in ocular tissues by the LSFG method is high, and the measurement time is shorter than that of laser Doppler velocimetry.<sup>8,9</sup> The LSFG method is therefore suitable for monitoring changes in

ocular tissue circulation at the same site during the course of a disease process.<sup>10</sup>

To the best of our knowledge, data have not been reported on the effects of vitrectomy on the ocular blood flow in eyes with a macular hole (MH) or an epiretinal membrane (ERM). In addition, there have been no reports on the investigation of the alterations of ocular blood flow during the vitrectomy in human eyes.

The purpose of this study was to determine the effect of vitrectomy on the ocular blood flow in patients with macular hole (MH) and epiretinal membrane (ERM). We measured the ocular blood flow of the optic nerve head, retinal vessels, and choroid before, during, and after vitrectomy by LSFG.

## **Materials and Methods**

### **Participants**

This study was conducted at the Nara Medical University from April 2011 through December 2011. Twenty subjects agreed to undergo the measurements and to have their medical records reviewed. The protocol of this study conformed to the tenets of the Declaration of Helsinki and was approved by the Internal Review Board of the Nara Medical University. The nature of the study was explained to all of the patients, and a signed informed consent was obtained.

There were 8 eyes with a MH and 12 eyes with an ERM, and there were 8 men

and 12 women whose mean  $\pm$  standard deviation of age was  $64.4 \pm 8.7$  years. The exclusion criteria included preoperative IOP above 22 mm Hg or patients who had been diagnosed with glaucoma, history of vitreous surgery, and age under 18 years.

### **Surgical methods**

One experienced vitreoretinal surgeon operated on all of the eyes with a 23-gauge vitrectomy system. Briefly, local anesthesia was induced by a subtenon injection of a mixture of 4% lidocaine and bupivacaine, and pars plana vitrectomy was performed using a 23-gauge vitrectomy system with vented gas forced infusion (Accurus Vitrectomy System; Alcon Labs, Fort Worth, TX, USA) under a wide-angle viewing system (Resight<sup>®</sup>, Carl Zeiss, Oberkochen, Germany). When there was a clinically significant lens opacity, the crystalline lens was removed by phacoemulsification and an intraocular lens was implanted before the vitrectomy.

### **Measurement of blood flow by laser speckle flowgraphy (LSFG)**

A LSFG instrument (Softcare, Fukuoka, Japan) was used to measure the blood flow of the optic nerve head, retinal vessels, and choroid based on the laser speckle phenomenon.<sup>10</sup> This instrument consisted of a fundus camera equipped with a halogen lamp and a diode laser. The images obtained with the halogen lamp were

used to identify the area to be examined. The laser light ( $\lambda = 830$  nm, maximum output power, 1.2 mW) was switched on at the time of the measurements. The measured fundus area was approximately 3.8 x 3 mm (width x height) with an estimated tissue penetration of 0.5 to 1 mm in human eyes.<sup>9</sup> The scattered laser light from the illuminated target area was photographed with a CCD camera with 700 x 480 pixel resolution. The light intensity of each pixel was converted into an electrical signal. Each imaging session lasted 4 seconds, and 120 frames (30/sec) were collected by a frame grabber and transferred to a computer file.<sup>11</sup> The offline analysis software (LSFG Analyzer) combined all images over the 4 seconds into a color-coded maps with each pixel being assigned a computed mean blur rate (MBR) which is a quantitative index of the relative blood flow velocity.<sup>10</sup> The MBR is the squared ratio of the mean intensity to the standard deviation of light intensity, which varies temporally and spatially according to the velocity of blood cells movement.<sup>10</sup> In the color-coded maps, a red color indicates high blood flow and blue color indicates low blood flow.<sup>10</sup>

We performed LSFG to quantitatively investigate the blood flow velocity (MBR) of the optic nerve head, retinal vessels, and choroid as reported.<sup>12-14</sup> Briefly, the optic disc in the color-coded map was segmented (Figure 1A), and separated into the optic nerve head area and the retinal vessel area (Figure 1B). Then the MBR of optic



nerve head and retinal vessels were extracted with a software (Discrimination Analysis of vascular and tissue perfusion) (Figure 1C). The MBR of the choroid was measured in the macular avascular region that was recorded as color-coded maps (Figure 1D).

The MBR was determined just before vitrectomy, during the vitrectomy, and 2 weeks and 1 month after the vitrectomy. During the vitrectomy, the infusion pressure of the vented gas forced infusion setting was set at 8, 20, and 40 mmHg, and MBR was determined at each infusion pressure by LSFG.

To evaluate changes in MBR, the changing rates of MBR against the baseline values (expressed as 100% of baseline) were used, because the MBR is a quantitative index of the 'relative' blood flow velocity.

### **Intraocular pressure and visual acuity**

The intraocular pressure (IOP) was measured with a Goldmann applanation tonometer before and 2 weeks and 1 month after the vitrectomy and with a Tono-Pen<sup>®</sup> XL applanation tonometer (Reichert Inc., Depew, New York, USA) during the vitrectomy.

The best-corrected visual acuity (BCVA) was measured at the same times as the IOP measurements before and after the vitrectomy by examiners who were masked

to the information obtained during the previous measurements. A Snellen chart was used to measure the BCVA, and the decimal acuity was converted to the logarithm of minimal angle of resolution (logMAR) for the statistical analyses.

### **Systemic hemodynamics**

The systolic blood pressure (SBP) and diastolic blood pressure (DBP) were measured at the upper arm by an automated oscillometric device. The mean arterial pressure (MAP) was calculated by the following equation:  $MAP = DBP + 1/3 (SBP - DBP)$ . The ocular perfusion pressure (OPP) was calculated by the following equation:  $OPP = 2/3 MAP - IOP$ . The pulse rate was automatically recorded by a finger pulse-oxymeter (HP-CMS Patient Monitor, Hewlett Packard, Palo Alto, CA) before, during, and 2 weeks and 1 month after the vitrectomy.

### **Statistical analyses**

Comparisons across the groups were done by one-way analysis of variance (ANOVA), and the Tukey–Kramer post hoc test was used when a significant difference was detected. The data are presented as the means  $\pm$  standard deviations (SDs). A *P* value  $<0.05$  was accepted as significant.

## Results

Four patients had systemic hypertension and 4 patients had hyperlipidemia. Pars plana vitrectomy was performed on 15 eyes combined with phacoemulsification and intraocular lens implantation (combined IOL), while pars plana vitrectomy alone was performed on 5 eyes (vitrectomy alone).

The relative MBRs of the optic nerve head, retinal vessels, and choroid decreased 2 weeks to 92.7%, 94.3%, and 94.9%, respectively,  $P > 0.05$ , single factor ANOVA, Figure 2). At 1 month, the MBR of the optic nerve head, retinal vessels, and choroid decreased to 91.9%, 94.0%, and 93.6%, respectively ( $P > 0.05$ , single factor ANOVA, Figure 2) after surgery compared to that of before the vitrectomy. None of the decreases in the different regions was significant. In addition, we also compared the blood flow in eyes that underwent vitrectomy alone to those underwent vitrectomy combined with phacoemulsification and intraocular lens implantation. There were no significant differences in the two groups in the relative MBRs of the optic nerve head, retinal vessels, and choroid at 2 weeks and 1 month after surgery compared to that of before the vitrectomy ( $P > 0.05$ , single factor ANOVA, Table 1).

The differences in the visual acuity, IOP (mmHg), basal pulse rate (bpm), OPP (mmHg), and MAP (mmHg) before and after 2 weeks and 1 month were not significant ( $P > 0.05$ , single factor ANOVA, Table 2).

During the vitrectomy, the IOP was significantly increased with increasing infusion pressure controlled by vented gas forced infusion system from 8 mmHg (IOP=15.1 ± 1.7 mmHg) to 20 mmHg (IOP=26.6 ± 3.3 mmHg,  $P = 0.001$ ), and to 40 mmHg (IOP=55.1 ± 4.4 mmHg,  $P = 0.001$ , Table 3). As a result, the OPP decreased significantly with increasing infusion pressure from 8 mmHg (OPP = 64.9 ± 9.8 mmHg) to 20 mmHg (OPP = 53.4 ± 10.1 mmHg,  $P = 0.001$ ), and to 40 mmHg (OPP = 24.9 ± 8.5 mmHg,  $P = 0.001$ , Table 3).

During vitrectomy, the relative MBRs of the optic nerve head, retinal vessels, and choroid decreased as the infusion pressure increased. An increase in the infusion pressure from 20 mmHg to 40 mmHg led to a significant decrease in the relative MBRs of the optic nerve head by 33.1% ( $P = 0.02$ ) and retinal vessels by 37.8% ( $P = 0.02$ ). There was also a decrease in relative MBRs of the optic nerve head (9.6% decrease) and retinal vessels (9.8% decrease) after increasing the infusion pressure from 8 mmHg to 20 mmHg but the differences were not significant (Figure 3).

The relative MBRs of the choroid was significantly reduced by 21.1% ( $P = 0.03$ ) after an increase of the infusion pressure from 8 mmHg to 20 mmHg and by 28.9% ( $P = 0.03$ ) from 20 mmHg to 40 mmHg (Figure 3). These results indicated that the choroidal blood flow was significantly reduced by increasing the infusion pressure.

During the vitrectomy, the mean blood pressure and pulse rate were not

significantly different (single factor ANOVA,  $P > 0.05$ , data not shown).

## Discussion

Earlier studies showed that the vitrectomy resulted in an increase of retinal oxygenation concentrations,<sup>15</sup> and an increase of retinal oxygenation concentrations leads to arterial vasoconstriction by autoregulation of the retinal blood flow.<sup>16</sup>

Human eyes have an autoregulatory mechanism for retinal blood flow. Thus, we assumed that the increased retinal oxygen levels after vitrectomy may cause vasoconstriction by autoregulation which would then decrease the retinal blood flow.

However, our LSFG results showed a slight decrease in blood flow two weeks and one month after the vitrectomy but the decrease was not significant compared to that before the vitrectomy. We did not measure the oxygen tension in our eyes and do not know if the increase was high enough to affect the retinal arteries. The other reason for this lack of change may be because eyes with an MH or an ERM may not have high concentrations of vasoactive factors in the vitreous.<sup>17</sup> Thus, the removal of the vitreous in patients with a MH or an ERM might not significantly alter the arterial vasoconstriction of the retinal vessels compared to that of observed in eyes with diabetic retinopathy,<sup>2-6</sup> then the degree of a decrease of blood flow was small.

The effect of the IOP and ocular blood flow during the vitrectomy in human eyes

have not been well examined. Recently, microincision vitrectomy system has become more common, and it is known that the removal of the vitreous by microincision vitrectomy system requires higher infusion pressures and suction forces compared to that of conventional 20-gauge system. We found that an increase in the infusion pressure from 8 mmHg to 20 mmHg and to 40 mmHg increased the IOP significantly. This would then mean that there was a significant decrease in the OPP which should then result in a decrease in the blood flow of the optic nerve head and retinal vessels. However, we found that the decrease was not significant when the infusion pressure was increased from 8 mmHg to 20 mmHg, but it was when the infusion pressure was 40 mmHg. The reason why the decrease between 8 mmHg to 20 mmHg was not significant may be because of autoregulation of the blood flow known to be present in the optic disc and retina of normal humans eyes.<sup>18-27</sup> The significant decrease at 40 mmHg infusion pressure may be due to a breakdown of autoregulation.<sup>23-31</sup>

The blood flow of the choroid was also significantly reduced with increasing infusion pressure from 8 mmHg to 20 mmHg and to 40mmHg. The choroid does not have autoregulation of blood flow<sup>32-36</sup> as do the optic nerve head and retinal vessels. Therefore, the blood flow of the choroid would be easily affected by alterations of the infusion pressure.

An increase in the IOP from 10 to 30 mm Hg in monkey eyes caused a significant decrease in the blood flow of the optic nerve head with lower systemic blood pressure.<sup>12</sup> The investigators suggested that stable systemic blood pressures and the IOP were important for maintaining normal blood flow of the optic nerve head, and thus also were important to prevent the progression of glaucoma.

Our results indicated that the higher infusion pressures required for microincision vitrectomy system altered the blood flow in the optic nerve head, retinal vessels, and choroid. Considering the results of a previous report,<sup>12</sup> these alterations of blood flow during the vitrectomy might be the cause of visual complications after vitrectomy. Thus, under the abnormal conditions in which autoregulation of the blood flow is lost, such as the eyes with diabetic retinopathy or glaucoma,<sup>37,38</sup> it is important to pay more attention to the increase of the infusion pressure during microincision vitrectomy system.

This is the first study that determined the ocular blood flow before, during, and after vitrectomy, and during vitrectomy by LSFG. A PubMed search with key words, 'laser speckle flowgraphy' and 'vitrectomy' did not extract any publications. Our results suggest that the vitrectomy can affect the ocular blood flow but only a limited retinal diseases were investigated. Thus, further investigations with longer follow-up periods, and a larger number of patients with different types of retinochoroidal

diseases are necessary.

In conclusion, the ocular blood flow did not change significantly before and after vitrectomy. However, a significant reduction of the blood flow of the optic nerve head, the retinal vessels, and the choroid was observed during the vitrectomy with high infusion pressures. More careful attention should be paid on the infusion pressures during the vitrectomy.



## References

- 1) Stefánsson E. Physiology of vitreous surgery. *Graefes Arch Clin Exp Ophthalmol.* 2009;247:147-163.
- 2) Kadonosono K, Itou N, Ohno S. Perifoveal microcirculation before and after vitrectomy for diabetic cystoid macular edema. *Am J Ophthalmol.* 2000;130:740-744.
- 3) Maeda K, Ishikawa F, Kobayashi K, Ohguro H. Examination of the optic nerve head blood flow in patients with proliferative diabetic retinopathy treated with vitrectomy. *J Jpn Ophthalmol Soc.* 2009;113:1132-1138.
- 4) Park JH, Woo SJ, Ha YJ, Yu HG. Effect of vitrectomy on macular microcirculation in patients with diffuse diabetic macular edema. *Graefes Arch Clin Exp Ophthalmol.* 2009;247:1009-1017.
- 5) Sullu Y, Hamidova R, Beden U, et al. Effects of pars plana vitrectomy on retrobulbar haemodynamics in diabetic retinopathy. *Clin Experiment Ophthalmol.* 2005;33:246-251.
- 6) Krepler K, Polska E, Wedrich A, Schmetterer L. Ocular blood flow parameters after pars plana vitrectomy in patients with diabetic retinopathy. *Retina.* 2003;23:192-196.

- 7) Tamaki Y, Araie M, Kawamoto E, Eguchi S, Fujii H. Noncontact, two-dimensional measurement of retinal microcirculation using laser speckle phenomenon. *Invest Ophthalmol Vis Sci.* 1994;35:3825-3834.
- 8) Nagahara M, Tamaki Y, Tomidokoro A, Araie M. In vivo measurement of blood velocity in human major retinal vessels using the laser speckle method. *Invest Ophthalmol Vis Sci.* 2011;52:87-92.
- 9) Tamaki Y, Araie M, Tomita K, et al. Real-time measurement of human optic nerve head and choroid circulation, using the laser speckle phenomenon. *Jpn J Ophthalmol.* 1997;41:49-54.
- 10) Sugiyama T, Araie M, Riva CE, Schmetterer L, Orgul S. Use of laser speckle flowgraphy in ocular blood flow research. *Acta Ophthalmol.* 2010;88:723-729.
- 11) Fujii H, Nohira K, Yamamoto Y, Ikawa H, Ohura T. Evaluation of blood flow by laser speckle image sensing. Part 1. *Appl Opt.* 1987;26:5321-5325.
- 12) Liang Y, Downs JC, Fortune B, et al. Impact of systemic blood pressure on the relationship between intraocular pressure and blood flow in the optic nerve head of nonhuman primates. *Invest Ophthalmol Vis Sci.* 2009;50:2154-2160.
- 13) Wang L, Cull GA, Piper C, Burgoyne CF, Fortune B. Anterior and posterior optic nerve head blood flow in nonhuman primate experimental glaucoma model

- measured by laser speckle imaging technique and microsphere method. *Invest Ophthalmol Vis Sci.* 2012;53:8303-8309.
- 14) Saito M, Saito W, Hashimoto Y, et al. Macular choroidal blood flow velocity decreases with regression of acute central serous chorioretinopathy. *Br J Ophthalmol.* 2013;97:775-780.
- 15) Holekamp NM, Shui YB, Beebe DC. Vitrectomy surgery increases oxygen exposure to the lens: A possible mechanism for nuclear cataract formation. *Am J Ophthalmol.* 2005;139:302-310.
- 16) Luksch A, Garhöfer G, Imhof A, et al. Effect of inhalation of different mixtures of O<sub>2</sub> and CO<sub>2</sub> on retinal blood flow. *Br J Ophthalmol.* 2002;86:1143-1147.
- 17) Ogata N, Nishikawa M, Nishimura T, Mitsuma Y, Matsumura M. Unbalanced vitreous levels of pigment epithelium-derived factor and vascular endothelial growth factor in diabetic retinopathy. *Am J Ophthalmol.* 2002;134:348-353.
- 18) Alm B, Bill A. Ocular and optic nerve head blood flow at normal and increased intraocular pressure in monkeys (*Macaca irus*): a study with radioactively labeled microspheres including flow determinations in brain and some other tissues. *Exp Eye Res.* 1973;15:15-29.
- 19) Weinstein JM, Funsch D, Page RB, Brennan RW. Optic nerve blood flow and its regulation. *Invest Ophthalmol Vis Sci.* 1982;23:640-645.

- 20) Weinstein JM, Duckrow RB, Beard D, Brennan RW. Regional optic nerve blood flow and its autoregulation. *Invest Ophthalmol Vis Sci.* 1983;24:1559-1565.
- 21) Riva CE, Hero M, Titze P, Petrig B. Autoregulation of human optic nerve head blood flow in response to acute changes in ocular perfusion pressure. *Graefes Arch Clin Exp Ophthalmol.* 1997;235:618-626.
- 22) Movaffaghy A, Chamot SR, Petrig BL, Riva CE. Blood flow in the human optic nerve head during isometric exercise. *Exp Eye Res.* 1998;67:561-568.
- 23) Geijer C, Bill A. Effects of raised intraocular pressure on retinal, prelaminar, laminar, and retrolaminar optic nerve blood flow in monkeys. *Invest Ophthalmol Vis Sci.* 1979;18:1030-1042.
- 24) Sossi N, Anderson DR. Effect of elevated intraocular pressure on blood flow: occurrence in cat optic nerve head studied with iodoantipyrine I 125. *Arch Ophthalmol.* 1983;101:98-101.
- 25) Tamaki Y, Araie M, Kawamoto E, Eguchi S, Fujii H. Non-contact, two-dimensional measurement of tissue circulation in choroid and optic nerve head using laser speckle phenomenon. *Exp Eye Res.* 1995;60:373-383.
- 26) Pillunat LE, Anderson DR, Knighton RW, Joos KM, Feuer WJ. Autoregulation of human optic nerve head circulation in response to increased intraocular pressure. *Exp Eye Res.* 1997;64:737-744.

- 27) Takayama J, Tomidokoro A, Ishii K, et al. Time course of optic nerve head circulation change after acute increase in intraocular pressure. *Invest Ophthalmol Vis Sci.* 2003;44:3977-3985.
- 28) Riva CE, Grunwald JE, Petrig BL. Autoregulation of human retinal blood flow. An investigation with laser Doppler velocimetry. *Invest Ophthalmol Vis Sci.* 1986;27:1706-1712.
- 29) Riva CE, Sinclair SH, Grunwald JE. Autoregulation of retinal circulation in response to decrease of perfusion pressure. *Invest Ophthalmol Vis Sci.* 1981;21:34-38.
- 30) Schulte K, Wolf S, Arend O, et al. Retinal hemodynamics during increased intraocular pressure. *Ger J Ophthalmol.* 1996;5:1-5.
- 31) Riva CE, Cranstoun SD, Petrig BL. Effect of decreased ocular perfusion pressure on blood flow and the flicker-induced flow response in the cat optic nerve head. *Microvasc Res.* 1996;52:258-269.
- 32) Armaly MF, Araki M. Effects of ocular pressure on choroidal circulation in the cat and Rhesus monkey. *Invest Ophthalmol Vis Sci.* 1975;14:584-591.
- 33) Yu DY, Alder VA, Cringle SJ, Brown MJ. Choroidal blood flow measured in the dog eye in vivo and in vitro by local hydrogen clearance polarography: validation

- of a technique and response to raised intraocular pressure. *Exp Eye Res.* 1988;46:289-303.
- 34) Gherezghiher T, Okubo H, Koss MC. Choroidal and ciliary body blood flow analysis: application of laser Doppler flowmetry in experimental animals. *Exp Eye Res.* 1991;53:151-156.
- 35) Alm A, Bill A. Blood flow and oxygen extraction in the cat uvea at normal and high intraocular pressure. *Acta Physiol Scand.* 1970;80:19-28.
- 36) Alm A, Bill A. Ocular and optic nerve blood flow at normal and increased intraocular pressures in monkeys: a study with labelled microspheres including flow determinations in brain and some other tissues. *Exp Eye Res.* 1973;15:15-29.
- 37) Rassam SM, Patel V, Kohner EM. The effect of experimental hypertension on retinal vascular autoregulation in humans: a mechanism for the progression of diabetic retinopathy. *Exp Physiol.* 1995;80:53-68.
- 38) Grieshaber MC, Mozaffarieh M, Flammer J. What is the link between vascular dysregulation and glaucoma?. *Surv Ophthalmol.* 2007;52:S144-S154.

## Figure legends

**Figure 1.** Mean blur rate (MBR) determined by laser speckle flowgraphy (LSFG).

A. Color-coded map of LSFG that shows the blood flow of the optic nerve head and retinal vessels. Red color indicates high blood flow and blue color indicates low blood flow. The optic disc (open circle) was segmented for analyzing the MBR of optic nerve head and retinal vessels.

B. Optic disc was separated from the retinal vessel area for the color-coded map.

C. The MBR of optic nerve head (black color area) and retinal vessels (white color area) were then extracted from the recoded color coded map by the embedded software.

D. Color-coded map of LSFG showing the blood flow of the choroid. Red color indicates high-blood flow and blue color indicates low blood flow. The blood flow of the choroid was measured in the macular avascular region (open circle), and the MBR was extracted by the embedded software tool.

**Figure 2.** Alterations of the relative MBR before and after vitrectomy.

The relative MBRs are calculated relative to the preoperative value (base line) which is set to 100%. Relative MBR values of the optic nerve head (■), retinal vessels (▲), and choroid (●) decreased 2 weeks and 1 month after surgery compared to

that of before the vitrectomy but the differences were not significant ( $P > 0.05$ , single factor ANOVA).

**Figure 3.** Alterations of the relative MBR with increasing the infusion pressure during vitrectomy. Relative MBR value is calculated as a ratio of the value at the baseline of 8 mmHg infusion pressure which is expressed as 100%. Relative MBR values of the optic nerve head (■), retinal vessels (▲), and choroid (●) decreased according to an increase in the infusion pressure controlled by vented gas forced infusion system during the vitrectomy. An increase in the infusion pressure from 20 mmHg to 40 mmHg led to a significant decrease in relative MBR values of the optic nerve head by 33.1% ( $P = 0.02$ ) and retinal vessels by 37.8% ( $P = 0.02$ ). There was also a decrease in relative MBR values of the optic nerve head and retinal vessels after increasing the infusion pressure from 8 mmHg to 20 mmHg but the differences were not significant. Relative MBR values of the choroid were significantly reduced by 21.1% ( $P = 0.03$ ) after an increase in the infusion pressure from 8 mmHg to 20 mmHg and also by 28.9% ( $P = 0.03$ ) from 20 mmHg to 40 mmHg.

(\*:  $P < 0.05$  vs. 8 mmHg, #:  $P < 0.05$  vs. 20 mmHg, single factor ANOVA).



**Table 1.** Comparison of vitrectomy alone and combined IOL regarding the relative MBRs before and after vitrectomy.

Combined IOL: vitrectomy combined with phacoemulsification and intraocular lens implantation

Values are expressed as mean  $\pm$  SD

**Table 2.** Systemic hemodynamics and ophthalmological data before and after the vitrectomy.

IOP: intraocular pressure

MAP: mean arterial pressure

OPP: ocular perfusion pressure

PR: pulse rate

Values are expressed as means  $\pm$  SD

**Table 3.** Alterations of the intraocular pressure and ocular perfusion pressure according to the increase of infusion pressure by vented gas forced infusion system during the vitrectomy.

\*:  $P < 0.05$  vs. 8 mmHg

#:  $P < 0.05$  vs. 20 mmHg

IOP: intraocular pressure

OPP: ocular perfusion pressure

Values are expressed as means  $\pm$  SDs

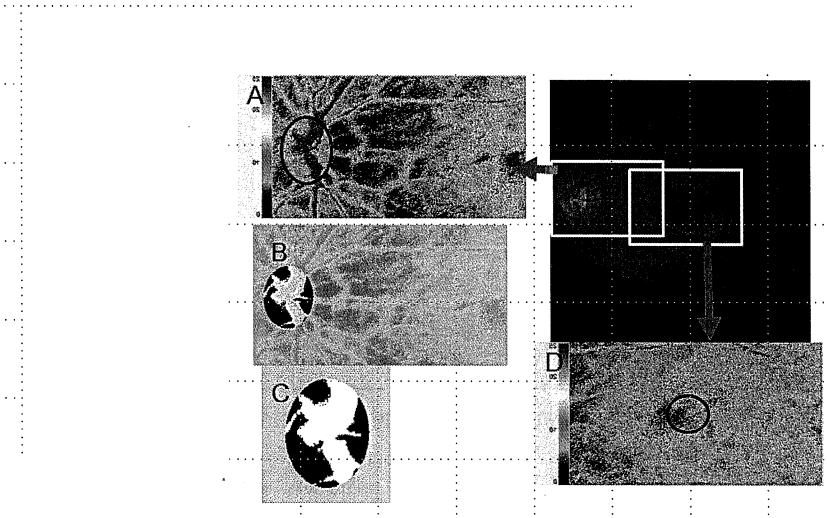


Figure 1

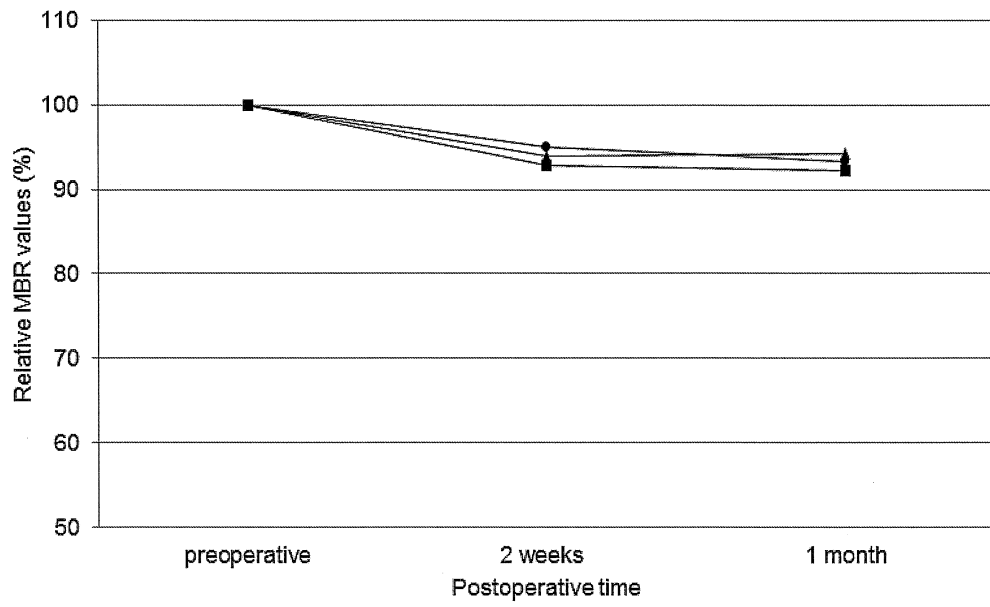


Figure 2

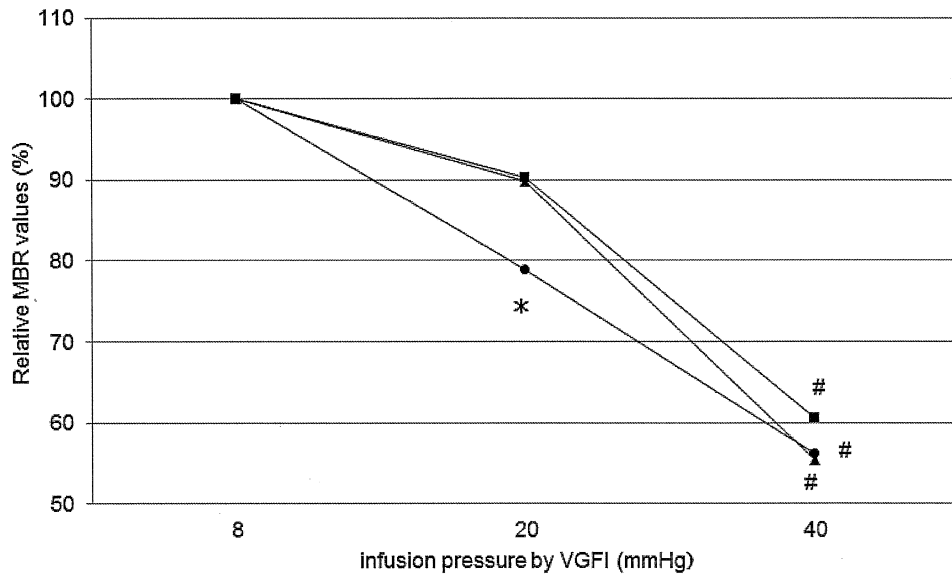


Figure 3

Table 1. Comparison of vitrectomy alone and combined IOL regarding the relative MBRs before and after vitrectomy.

	Before surgery	2 weeks after surgery	1 month after surgery
Vitrectomy alone (n=5)			
optic nerve head	100	92.9±2.4	92.2±1.9
retinal vessels	100	94.5±2.0	94.3±2.1
choroid	100	95.0±1.8	93.3±1.6
Combined IOL (n=15)			
optic nerve head	100	92.4±2.1	91.6±2.5
retinal vessels	100	94.0±2.4	93.6±1.7
choroid	100	94.8±1.9	93.8±1.9

Combined IOL: vitrectomy combined with phacoemulsification and intraocular lens implantation

Values are expressed as mean ± SD

Table 2. Systemic hemodynamics and ophthalmological data before and after the vitrectomy.

N=20	Before surgery	2 weeks after surgery	1 month after surgery
logMAR	0.37±0.22	0.3±0.21	0.33±0.25
IOP (mmHg)	14.8±4.1	15.2±3.8	14.2±3.2
MAP (mmHg)	94.5±12.2	91.8±11.8	92.1±9.6
OPP (mmHg)	80.7±13.0	77.1±12.3	78.6±12.3
PR (bpm)	62.0±8.4	60.6±7.5	61.0±8.8

IOP: intraocular pressure

MAP: mean arterial pressure

OPP: ocular perfusion pressure

PR: pulse rate

Values are expressed as mean±SD

Table 3. Alternation of intraocular pressure and ocular perfusion pressure according to the increase of infusion pressure by vented gas forced infusion system during the vitrectomy.

vented gas forced infusion pressure (mmHg)	8	20	40
IOP(mmHg)	15.1±1.7	26.6±3.3*	55.1±4.4 #
OPP(mmHg)	64.9±9.8	53.4±10.1*	24.9±8.5 #

\*:  $P < 0.05$  vs. 8mmHg

#:  $P < 0.05$  vs. 20mmHg

IOP: intraocular pressure

OPP: ocular perfusion pressure

Values are expressed as mean ± SD