




Contents lists available at ScienceDirect

Interdisciplinary Neurosurgery: Advanced Techniques and Case Management

journal homepage: www.elsevier.com/locate/inat

Research Article

Efficacy of autogenous bone grafts preserved in 80% ethanol solution for preventing surgical site infection after cranioplasty: A retrospective cohort study

Yohei Kogeichi^{a,b}, Yasushi Motoyama^{c,*}, Yasuhiro Takeshima^a, Ryosuke Matsuda^a,
Kentarō Tamura^a, Fumihiko Nishimura^a, Shuichi Yamada^a, Ichiro Nakagawa^a,
Young-Su Park^a, Hidetada Fukushima^b, Hiroyuki Nakase^a

^a Department of Neurosurgery, Nara Medical University, Kashihara, Nara 634-8522, Japan

^b Department of Emergency and Critical Care Medicine, Nara Medical University, Kashihara, Nara 634-8522, Japan

^c Department of Neurology, Osaka Police Hospital, Osaka 543-0035, Japan



ARTICLE INFO

Keywords:

Autogenous bone graft
Decompressive craniectomy
Ethanol
Surgical site infection

ABSTRACT

Background: Surgical site infection (SSI) is common following cranioplasty after decompressive craniectomy (DC). The aim of this study was to assess the risk of SSI following cranioplasty in terms of the preservation method of autogenous bone graft (ABG), comparing preservation in 80% ethanol versus the standard method of subcutaneous ABG preservation.

Material and methods: The patients who underwent cranioplasty using ABGs after DC between 2008 and 2019 were retrospectively reviewed. SSIs were compared between patients whose ABG was preserved in 80% ethanol (group A) and those whose ABG was preserved subcutaneously (group B) using inverse probability of treatment weighting (IPTW) based on propensity scores to balance measurable confounders including elderly age, sex, expanded polytetrafluoroethylene, stroke, interval to cranioplasty, and diabetes mellitus.

Results: Total number of 127 patients consisted of 56 in group A and 71 in group B. SSI after cranioplasty occurred in five patients each in groups A and B (8.9% vs. 7%, $p = 0.748$). IPTW analysis demonstrated that preservation in 80% ethanol was associated with a lower risk of SSI (odds ratio: 0.239, 95% confidence interval: 0.0615–0.927, $p = 0.039$).

Conclusion: The simple and less-invasive method of preserving ABGs in 80% ethanol for cranioplasty after DC might be potentially safe from an SSI perspective.

1. Introduction

Decompressive craniectomy (DC) with duraplasty reportedly improves the survival rate of acute cerebral edema due to malignant cerebral infarction [1–3], traumatic brain injury [4–6], and subarachnoid hemorrhage (SAH) [7,8]. After the cerebral edema subsides, cranioplasty is necessary to prevent deformity of the head and the sinking skin flap syndrome [9]. Although artificial bone material can be used for cranioplasty, if needed, care should be taken to avoid infection in such cases. Furthermore, the artificial bone flap needs to be made to order using three-dimensional computed tomography and is expensive. On the other hand, an autogenous bone graft (ABG) is less expensive and is less likely to get infected [10]. When an ABG is used for cranioplasty, the

bone flap that is removed at the time of DC is often preserved subcutaneously in the thigh or abdomen, or in a freezer, until cranioplasty. These methods of preservation of the ABG are associated with certain disadvantages, including the risk of surgical site infection (SSI) and bone graft resorption in the case of cryopreservation [11], and increased invasiveness due to the need for surgery at another site for placement of the graft when using subcutaneous preservation.

Another simple method of preservation of ABGs in a solution of 80% ethanol has been reported [12]. However, there have been no reports about the risk of SSIs with this method. The aim of this study was to compare bone graft preservation using an 80% ethanol solution with subcutaneous preservation of the graft in the thigh with regards to the risk of SSI.

* Corresponding author at: Department of Neurosurgery, Osaka Police Hospital, 10-35 Kitayama-cho, Tenouji-ku, Osaka city, Osaka 543-0035, Japan.

E-mail address: myasushi@naramed-u.ac.jp (Y. Motoyama).

<https://doi.org/10.1016/j.inat.2022.101489>

Received 24 July 2021; Received in revised form 26 December 2021; Accepted 2 January 2022

Available online 7 January 2022

2214-7519/© 2022 The Author(s). Published by Elsevier B.V. This is an open access article under the CC BY-NC-ND license (<http://creativecommons.org/licenses/by-nc-nd/4.0/>).

2. Methods

2.1. Ethics statement

All research protocols in this study were approved by the institutional review board of Nara Medical University (approval number: 3062), and the need for informed consent was waived.

2.2. Study design and patient selection

This retrospective, cohort study included patients who underwent cranioplasty following DC at Nara Medical University, Japan, between 2008 and 2019. The patients' characteristics, such as the original pathology and their medical history, the material used as a dura substitute in DC, and the preservation method of the ABG during the period between DC and cranioplasty were evaluated.

Patients who underwent cranioplasty using ABGs were divided into group A, in whom the ABG after DC was preserved in an 80% ethanol solution, and group B, in which the ABG was preserved subcutaneously in the thigh.

To reduce selection bias and ensure reliably comparable cohorts, the propensity score for treatment was calculated by logistic regression analysis using inverse probability of treatment weighting (IPTW). Then, using synthetic cohorts, whether preservation in 80% ethanol was associated with SSIs was investigated (Fig. 1).

2.3. Inclusion and exclusion criteria

This study included patients who underwent cranioplasty using ABGs along with duraplasty after DC performed to reduce elevated intracranial pressure due to a variety of pathologies, including acute cerebral infarction, aneurysmal SAH (aSAH), traumatic brain injury, and other diseases. The following patients were excluded: 1. those who underwent DC but died before cranioplasty; 2. patients who underwent DC of the posterior fossa, because subsequent cranioplasty is often unnecessary; 3. patients who underwent cranioplasty using an artificial bone graft, for example, when a free bone flap was abandoned because of an open head injury; and 4. patients who could not be followed for at least one year.

2.4. Definition of SSI

In this study, SSI was defined as apparent local inflammation due to infection at the surgical site that required surgical removal of the bone

flap.

2.5. Clinical outcome

The primary endpoint was defined as the occurrence of SSI within one year after cranioplasty following DC. The secondary endpoint was the occurrence of autogenous bone resorption.

2.6. Surgical technique

DC was performed by removing a large frontotemporal-parietal bone flap. The dura was opened widely and was covered by expanded polytetrafluoroethylene (ePTFE) or fascia lata, which was selected based on the surgeon's judgement.

After DC and until cranioplasty, the ABG was preserved either subcutaneously or in an 80% ethanol solution, based on the surgeon's judgement.

When the ABG was preserved in 80% ethanol (Nipro Corporation, Osaka, Japan), the bone flap that was removed from the surgical field was first cleansed and irrigated with a saline solution. Then, it was soaked in the 80% ethanol solution and packed in a sterile transparent plastic container. Thereafter, the container was placed in a sterile plastic bag and sealed. The package was stored in the medical refrigerator at 4 °C until cranioplasty.

Cranioplasty was usually performed between 2 and 4 weeks after the cerebral edema had subsided and the patient's general condition was confirmed to be stable.

In both groups, antibiotic prophylaxis was routinely administered prior to incision within 30 min, and 3 h from the beginning of the operation the antibiotic was added. No antibiotic was given postoperatively.

2.7. Comparison of risk of SSI

To compare the risk of SSI after cranioplasty, the following factors were evaluated: age (dichotomously divided as ≤ 60 years and > 60 years), sex, type of disease (classified as stroke, including malignant infarction and aSAH, and other pathologies, including trauma and brain tumor), use of ePTFE as the material for duraplasty, and a history of diabetes mellitus (DM). Since use of ePTFE and the pathology of stroke causing cerebral edema have been reported as risk factors related to SSI in cranioplasty after DC, they were included as confounding factors for adjustment [13,14].

Furthermore, the interval between DC and cranioplasty has been reported to be associated with the occurrence of SSI [10,15–17]. Therefore, the interval to cranioplasty was also included as a covariate in the propensity score analysis.

2.8. Statistical analysis

Continuous variables are presented as means \pm standard deviation. All dichotomous variables are reported as percentages. Univariate analysis was performed using Fisher's exact test to evaluate the risk of SSI.

Multivariable analysis was performed using logistic regression to evaluate the risk of SSI for reference, even though the number of outcomes was small.

Propensity score analyses were used to balance measurable confounders between groups A and B. Multivariable logistic regression was used to predict treatment (preservation method of ABG in 80% ethanol) based on confounding covariates, including elderly age, sex, ePTFE, stroke, interval to cranioplasty, and DM. Each patient was then assigned an estimated propensity score, which was his/her predicted probability of receiving the preservation method of ABG in 80% ethanol based on his/her observed baseline characteristics.

Logistic regression analyses were also performed by applying

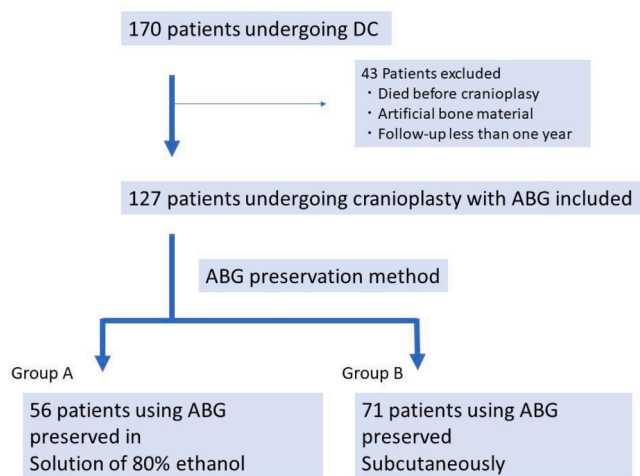


Fig. 1. Flow chart of the study population. DC ; decompressive craniectomy, ABG; autogenous bone graft.

propensity scores to adjust for group differences in two alternative ways: (1) regression adjustment (i.e., inclusion of the propensity score as a linear predictor in the model); and (2) use of the propensity score to create stabilized weights, defined as the inverse probability of treatment weighting (IPTW) [18].

For reference, multivariable logistic regression for the risk of SSI was also analyzed, even though the number of patients who achieved the outcome was small.

A *p* value of ≤ 0.05 was considered significant if the 95% confidence interval (CI) did not include 1. All statistical analyses were performed using EZR Ver.1.53 software (Saitama Medical Center, Jichi Medical University, Saitama, Japan), which is a graphical user interface for R (The R Foundation for Statistical Computing, Vienna, Austria).

3. Results

3.1. Baseline characteristics of patients undergoing cranioplasty

A total of 172 patients who underwent DC during the study period were retrospectively reviewed; cranioplasty was performed in 149 patients, and artificial bone material was used in 22 patients. The remaining 127 patients who met the inclusion criteria were divided into group A (*n* = 56), in which the ABG was preserved in an 80% ethanol solution for cranioplasty, and group B (*n* = 71), in which the ABG was preserved subcutaneously.

In group A, the average age of the patients was 51.6 ± 22.6 years. Twenty-two were female and 34 were male. The causative pathology of cerebral edema was stroke, including malignant brain infarction and aSAH in 18 patients, and other diseases, including traumatic brain injury and brain tumors in 38 patients. ePTFE was used for duraplasty following DC in 48 patients. Five of the 56 patients had DM.

In group B, the average age of the patients was 56.0 ± 19 years. There were 27 females and 44 males. The pathology of the brain swelling was stroke in 43 and other disease in 28 patients. ePTFE was used for duraplasty in 10 patients, and nine patients had DM.

The average follow-up period of group A was 2.25 ± 1.6 years, ranging from one to 6 years, whereas the follow-up period of group B was 5.7 ± 2.9 years, ranging from one to 12 years (Table 1).

3.2. Clinical outcomes

A total of 10 patients developed SSI. The timing of development of SSI after cranioplasty ranged from 4 to 240 days, with an average of 44.1 ± 64.8 days. The mean day of SSI development was 20 days.

SSI after cranioplasty occurred in five patients each in groups A and B (8.9% vs. 7%, *p* = 0.748). Multivariable logistic regression analysis demonstrated that 80% ethanol was not significantly associated with SSI (odds ratio [OR]: 0.274, 95% confidence interval [CI]: 0.049–1.53, *p* = 0.14). Furthermore, the regression model of the preservation method of ABG in 80% ethanol using the propensity score as a covariate demonstrated a similar OR, with no significant difference (OR: 0.259, 95%CI: 0.0516–1.3, *p* = 0.0975). On IPTW analyses, however, the occurrence of SSIs was significantly lower with preserving the ABG in 80% ethanol than with the standard subcutaneous preservation (OR: 0.239, 95%CI: 0.0615–0.927, *P* = 0.039) (Tables 2 and 3).

None of the patients in either group developed bone graft resorption.

4. Discussion

In this study, the risk of infection was shown to be potentially lower with ABG preserved in an 80% ethanol solution than with the standard method of subcutaneous preservation of the bone graft.

In the present study, multivariable logistic regression analysis suggested that the use of ePTFE was the strongest risk factor related to SSI. Use of ePTFE as the material in DC has been reported to be a potential source of infection [14]. Similarly, stroke pathology was also reported to

Table 1

Characteristics of the patients in both groups in which autogenous bone flap was preserved in 80% ethanol and the standard subcutaneous method.

	Total number (<i>n</i> = 127)	80% ethanol Group A (<i>n</i> = 56)	Standard Group B (<i>n</i> = 71)	<i>p</i> value
Average age (years old \pm SD)	54.0 \pm 20.6	51.61 \pm 22.6	55.97 \pm 19.0	0.24
Female sex	49 (38.6%)	22 (39.3%)	27 (38.0%)	1
<i>Pathology causing DC</i>				0.007
cerebral infarction	29 (22.8%)	9 (16.1%)	20 (28.2%)	
SAH	32 (25.2%)	9 (16.1%)	23 (32.4%)	
traumatic head injury	60 (47.2%)	36 (64.3%)	24 (33.8%)	
other	6(4.7%)	2 (3.6%)	4 (5.6%)	
<i>Past history</i>				
DM	14(11%)	5 (8.9%)	9 (12.7%)	0.578
HT	49 (38.6%)	21 (37.5%)	28 (39.4%)	0.856
cancer	5(3.9)	2 (3.6%)	3 (4.2%)	1
<i>Cranioplasty</i>				
Duration after DC (days \pm SD)	40.0 \pm 27.1	37.64 \pm 32.1	41.65 \pm 22.8	0.412
ePTFE	58 (45.7%)	48 (85.7)	10 (14.1%)	<0.001
Surgical site infection (7.9%)	10	5(8.9%)	5(7%)	0.748
Follow up period (yrs)	4.2 \pm 2.9	2.3 \pm 1.6	5.7 \pm 2.9	<0.001

DC; decompressive craniectomy, DM; diabetes mellitus, ePTFE; expanded polytetrafluoroethylene, HT; hypertension, SAH; subarachnoid hemorrhage, SD; standard deviation

be a risk for SSI after DC [13]. Thus, the effect of these potential confounders was eliminated by propensity score analyses to obtain the results of the study. Similar ORs on propensity score analyses were shown with both the regression model and the IPTW method. However, the *p*-value was significant in the IPTW method, but not in the regression model. The approach using regression analyses assumes that the relationship between the propensity score and the outcome is correctly modeled. However, this approach should be used carefully, because the bias might increase when the variances in the treatment and control groups are very different [19]. On the other hand, using stabilized IPTW preserves the sample size of the original data and produces an appropriate estimate of the variance of treatment effects [20].

Preservation of ABGs in an 80% ethanol solution eliminates the risk of infection during the storage period. Additionally, we hypothesized that the lower likelihood of SSI with ABGs preserved in 80% ethanol is due to the effect of the high concentration of ethanol. Ethanol, or ethyl alcohol, is strongly bactericidal rather than bacteriostatic against vegetative forms of bacteria; it is also tuberculocidal, fungicidal, and virucidal, although it does not destroy bacterial spores. The cidal activity decreases sharply when it is diluted to below a 50% concentration, and the optimum bactericidal concentration is a 60%–90% solution in water (volume/volume) [21,22].

Cryopreservation of bone grafts in the freezer has been previously reported [23], and cryopreservation of ABGs has been reported to be safe [24]. On the other hand, bone resorption of moderate and severe grades occurred at a rate of 7.5% and 6.0%, respectively. In the present study, although the follow-up period was limited, bone graft resorption was not apparent in any of the cases.

Future comparative studies are needed to elucidate the risk and

Table 2
Covariates used for inverse probability of treatment weighting analysis and standard mean difference.

Covariate	Crude cohort			Adjusted cohort by IPTW		
	80% ethanol (n = 56)	Standard (n = 71)	SMD before IPTW	80% ethanol (n = 48.1)	Standard (n = 77.4)	SMD after IPTW
Elderly (%)	23 (41.1%)	32 (45.1%)	0.081	28.8 (37.2)	17.4 (36.2)	0.022
Sex (%)	22 (39.3%)	27 (38.0%)	0.026	33.9 (43.8)	21.0 (43.6)	0.004
DM (%)	5 (8.9%)	9 (12.7%)	0.121	7.2 (9.3)	5.3 (11.0)	0.058
Stroke (%)	18 (32.1%)	43 (60.6%)	0.595	31.9 (41.2)	15.8 (32.9)	0.172
ePTFE (%)	48 (85.7%)	10 (14.1%)	2.053	39.0 (50.4)	25.8 (53.6)	0.064
Early cranioplasty (<30 days)(%)	23 (41.1%)	23 (32.4%)	0.181	27.8 (35.9)	16.3 (34.0)	0.041

DM; diabetes mellitus, ePTFE:expanded polytetrafluoroethylene, IPTW; inverse probability treatment of weighting, SMD; standard mean difference

Table 3
Multivariable analyses of the preservation method of ABG in 80% ethanol for the risk of SSI.

Models	OR	95% CI		p value
		lower	upper	
Multivariable logistic regression				
80% Ethanol	0.274	0.049	1.53	0.14
Elderly	0.322	0.0561	1.85	0.203
Female	0.924	0.191	4.47	0.922
DM	0.000000142	0	Inf	0.992
Stroke	0.864	0.176	4.25	0.858
ePTFE	13.9	1.86	104	0.0103*
Early cranioplasty (<30 days)	0.157	0.0177	1.4	0.0975
Propensity score adjusted model				
Regression adjustment				
80% Ethanol	0.259	0.0516	1.3	0.1
Weighting (IPTW)				
80% Ethanol	0.239	0.0615	0.927	0.0385*

ABG; autogenous bone graft, CI; confidence interval, DM; diabetes mellitus, ePTFE; expanded polytetrafluoroethylene, IPTW; inverse probability treatment of weighting, OR; odds ratio, SSI; surgical site infection

*Statistically significant

benefit of each preservation method with a much larger sample size.

5. Limitations

The small number of patients, retrospective study design, and the single-center research are limitations of this study.

In the present study, systemic infections, blood glucose level, bone defect size, hospitalization length, discharge to institutional care, and hospital bed size, which are potential contributors to the occurrence of SSI [25,26] could not be included as covariates in the propensity score analysis, because the detailed data were not available and the present study was not multi-center survey.

Randomized studies are necessary to eliminate confounding factors and identify more reliable factors.

6. Conclusion

The risk of SSI related to cranioplasty after DC using ABGs preserved in an 80% ethanol solution did not increase in comparison with the subcutaneous preservation method.

None of the patients experienced autogenous bone resorption after cranioplasty with ABGs preserved in 80% ethanol. Thus, preservation of ABGs in 80% ethanol might be simple, low-cost, and safe for cranioplasty after DC.

CRedit authorship contribution statement

Yohei Kogeichi: Conceptualization, Methodology. **Yasushi Motoyama:** Writing – original draft. **Yasuhiro Takeshima:** Data

curation. **Ryosuke Matsuda:** Data curation. **Kentaro Tamura:** Data curation. **Fumihiko Nishimura:** Visualization. **Shuichi Yamada:** . **Ichiro Nakagawa:** Writing – review & editing. **Young-Su Park:** Validation. **Hidetada Fukushima:** Supervision. **Hiroyuki Nakase:** Supervision.

Declaration of Competing Interest

The authors declare that they have no known competing financial interests or personal relationships that could have appeared to influence the work reported in this paper.

References

- [1] J. Hofmeijer, L.J. Kappelle, A. Algra, G.J. Amelink, J. van Gijn, H.B. van der Worp, Surgical decompression for space-occupying cerebral infarction (the Hemicraniectomy After Middle Cerebral Artery infarction with Life-threatening Edema Trial [HAMLET]): a multicentre, open, randomised trial, *Lancet Neurol.* 8 (4) (2009) 326–333.
- [2] K. Vahedi, E. Vicaut, J. Mateo, et al., Sequential-design, multicenter, randomized, controlled trial of early decompressive craniectomy in malignant middle cerebral artery infarction (DECIMAL Trial), *Stroke* 38 (9) (2007) 2506–2517.
- [3] E. Jüttler, S. Schwab, P. Schmiedek, et al., Decompressive Surgery for the Treatment of Malignant Infarction of the Middle Cerebral Artery (DESTINY): a randomized, controlled trial, *Stroke* 38 (9) (2007) 2518–2525.
- [4] D.W. Marion, Decompressive craniectomy in diffuse traumatic brain injury, *Lancet Neurol.* 10 (6) (2011) 497–498.
- [5] D.J. Cooper, J.V. Rosenfeld, L. Murray, et al., Decompressive craniectomy in diffuse traumatic brain injury, *N. Engl. J. Med.* 364 (16) (2011) 1493–1502.
- [6] J. Albanese, M. Leone, J.-R. Alliez, et al., Decompressive craniectomy for severe traumatic brain injury: evaluation of the effects at one year, *Crit. Care Med.* 31 (10) (2003) 2535–2538.
- [7] C.M. Schirmer, D.A. Hoit, A.M. Malek, Decompressive hemicraniectomy for the treatment of intractable intracranial hypertension after aneurysmal subarachnoid hemorrhage, *Stroke* 38 (3) (2007) 987–992.
- [8] U. Buschmann, Y. Yonekawa, M. Fortunati, E. Cesnulis, E. Keller, Decompressive hemicraniectomy in patients with subarachnoid hemorrhage and intractable intracranial hypertension, *Acta Neurochirurgica.* 149 (1) (2007) 59–65.
- [9] A. Yamaura, H. Makino, Neurological deficits in the presence of the sinking skin flap following decompressive craniectomy, *Neurol. Med. Chir. (Tokyo).* 17 (1 Pt 1) (1977) 43–53.
- [10] V. Chang, P. Hartzfeld, M. Langlois, A. Mahmood, D. Seyfried, Outcomes of cranial repair after craniectomy, *J. Neurosurg.* 112 (5) (2010) 1120–1124.
- [11] I.P. Bhaskar, T.J.J. Inglis, G.Y.F. Lee, Clinical, radiological, and microbiological profile of patients with autogenous cranioplasty infections, *World Neurosurg.* 82 (3-4) (2014) e531–e534.
- [12] Y. Kurokawa, K. Watanabe, S. Abiko, T. Okamura, T. Yokoyama, Cranioplasty results using decompressed bone flaps preserved in 80% ethanol [in Japanese], *Jpn. J. Neurosurg. (Tokyo).* 4 (2) (1995) 128–132.
- [13] P. Dünisch, J. Walter, Y. Sakr, R. Kalf, A. Waschke, C. Ewald, Risk factors of aseptic bone resorption: a study after autologous bone flap reinsertion due to decompressive craniotomy, *J. Neurosurg.* 118 (5) (2013) 1141–1147.
- [14] S. Nakagawa, T. Hayashi, S. Anegawa, S. Nakashima, S. Shimokawa, Y. Furukawa, Postoperative infection after duraplasty with expanded polytetrafluoroethylene sheet, *Neurol. Med. Chir. (Tokyo)* 43 (3) (2003) 120–124, discussion 124.
- [15] F. Zheng, H. Xu, N. von Spreckelsen, et al., Early or late cranioplasty following decompressive craniotomy for traumatic brain injury: A systematic review and meta-analysis, *J. Int. Med. Res.* 46 (7) (2018) 2503–2512.
- [16] R.P. Morton, I.J. Abecassis, J.F. Hanson, et al., Timing of cranioplasty: a 10.75-year single-center analysis of 754 patients, *J. Neurosurg.* 128 (6) (2018) 1648–1652.
- [17] S. Chibbaro, F. Di Rocco, G. Mirone, et al., Decompressive craniectomy and early cranioplasty for the management of severe head injury: a prospective multicenter study on 147 patients, *World Neurosurg.* 75 (3-4) (2011) 558–562.
- [18] J.M. Robins, M.Á. Hernán, B. Brumback, Marginal structural models and causal inference in epidemiology, *Epidemiology.* 11 (5) (2000) 550–560.

- [19] D.B. Rubin, Using multivariate matched sampling and regression adjustment to control bias in observational studies, *ETS Res. Bull. Ser.* 1978 (2) (1978) i–33.
- [20] S. Xu, C. Ross, M.A. Raebel, S. Shetterly, C. Blanchette, D. Smith, Use of stabilized inverse propensity scores as weights to directly estimate relative risk and its confidence intervals, *Value Health.* 13 (2) (2010) 273–277.
- [21] H.E. Morton, The relationship of concentration and germicidal efficiency of ethyl alcohol, *Ann. N. Y. Acad. Sci.* 53 (1) (1950) 191–196.
- [22] S.S. Block, *Disinfection, Sterilization, and Preservation*, Lippincott Williams & Wilkins, Philadelphia, PA, 2001.
- [23] J.-H. Oh, J.E. Zöller, A. Kübler, A new bone banking technique to maintain osteoblast viability in frozen human iliac cancellous bone, *Cryobiology* 44 (3) (2002) 279–287.
- [24] J. Zhang, F. Peng, Z. Liu, et al., Cranioplasty with autogenous bone flaps cryopreserved in povidone iodine: a long-term follow-up study, *J. Neurosurg.* 127 (6) (2017) 1449–1456.
- [25] A. Alkhaibary, A. Alharbi, M. Abbas, et al., Predictors of surgical site infection in autologous cranioplasty: a retrospective analysis of subcutaneously preserved bone flaps in abdominal pockets, *World Neurosurg.* 133 (2020) e627–e632.
- [26] I.A. Buchanan, D.A. Donoho, A. Patel, et al., Predictors of surgical site infection after nonemergent craniotomy: a nationwide readmission database analysis, *World Neurosurg.* 120 (2018) e440–e452.