

# Anatomical Relations of the Perforators from the Descending Lateral Femoral Circumflex Artery and Vastus Lateralis Motor Nerve Branches

Hiroshi Okada, MD\*  
 Kenji Kawamura, MD\*  
 Hideo Hasegawa, MD\*  
 Shohei Omokawa, MD†  
 Pasuk Mahakkanukrauh, MD‡  
 Yasuhito Tanaka, MD\*

**Background:** The anterolateral thigh (ALT) flap, which is nourished by perforators from the descending branch of the lateral femoral circumflex artery (P), is one of the most commonly used flaps in soft tissue reconstruction. With the growing use of ALT flaps, attention toward donor-site morbidity has increased in recent years. Damage to the motor nerve branches of the vastus lateralis muscle (N) is one of the causes of donor-site morbidity, particularly muscle weakness. This study investigated the anatomical locations of the P and N in fresh-frozen cadaveric specimens. **Methods:** This study included 43 cadaver limbs. A silicone rubber compound (30 mL) was injected into the femoral artery to visualize the vessel. The locations of the P and motor points of N were measured to assess the risk of N injury during ALT flap harvesting.

**Results:** There were one to six (mean, 2.7) P and two to seven (mean, 4) N. When the two most proximal perforators were used for flap harvesting, an average of 1.5 motor nerve branches (42%) was damaged because transection of the motor nerve branches was required for flap harvesting. In 33% of the limbs, only one motor nerve branch remained after the flap harvest. However, there were no cases where all motor nerve branches were severed.

**Conclusion:** When an ALT flap with two perforators is harvested, weakness of the vastus lateralis muscle may occur in cases with a small number of motor nerve branches. (*Plast Reconstr Surg Glob Open* 2024; 12:e5611; doi: [10.1097/GOX.0000000000005611](https://doi.org/10.1097/GOX.0000000000005611); Published online 12 February 2024.)

## PURPOSE

The anterolateral thigh (ALT) flap, which is nourished by perforators from the descending branch of the lateral femoral circumflex artery, has been one of the most used flaps for soft tissue reconstruction.<sup>1</sup> Because of its various advantages such as long vascular pedicle, relatively large flap, and possible harvesting in the supine position, the ALT flap can be applied to reconstruction of almost all areas, including the head and neck, upper and lower extremities, hand, trunk, and even breast recipient sites.<sup>2-6</sup> It is also useful as a sensory flap by including

the lateral femoral cutaneous nerve<sup>6</sup> and as a functional reconstruction by harvesting with the vastus lateralis muscle.<sup>7</sup> The descending branch of the lateral femoral circumflex artery, of which perforator branches are feeding vessels for the ALT flap, and the motor nerve of the vastus lateralis muscle, which arises from the femoral nerve and divided to several branches running along the descending branch of the lateral femoral circumflex artery to innervate the vastus lateralis muscle, have many variations. Although there have been several anatomical studies on the lateral femoral circumflex artery<sup>2,8-10</sup> and motor nerve of the vastus lateralis muscle<sup>7,11,12</sup> on their own, the anatomical relationship between them has rarely been reported.<sup>13-15</sup>

Donor-site morbidities associated with the ALT flap have attracted increasing attention owing to its widespread use. Donor-site morbidity is as important as flap survival at the recipient site because it can affect a patient's quality of life. Disorders of the donor-site include muscle weakness, pain, sensory disturbances, and compartment syndrome.<sup>5,16-23</sup> Among these, musculoskeletal dysfunction is one of the most notable disorders causing decreased muscle power of knee extension and fatigue during gait.

From the \*Department of Orthopaedic Surgery, Nara Medical University, Nara, Japan; †Department of Hand Surgery, Nara Medical University, Nara, Japan; and ‡Department of Anatomy, Faculty of Medicine, Chiang Mai University, Chiang Mai, Thailand. Received for publication November 7, 2023; accepted December 28, 2023.

Copyright © 2024 The Authors. Published by Wolters Kluwer Health, Inc. on behalf of The American Society of Plastic Surgeons. This is an open-access article distributed under the terms of the [Creative Commons Attribution-Non Commercial-No Derivatives License 4.0 \(CCBY-NC-ND\)](https://creativecommons.org/licenses/by-nc-nd/4.0/), where it is permissible to download and share the work provided it is properly cited. The work cannot be changed in any way or used commercially without permission from the journal.

DOI: [10.1097/GOX.0000000000005611](https://doi.org/10.1097/GOX.0000000000005611)

Disclosure statements are at the end of this article, following the correspondence information.

Kimata et al reported that more than 75% of patients who seemed to perform activities of daily living normally complained of muscular weakness and fatigue at the donor-site.<sup>16</sup> Weise et al reported that maximum torque was measured for extension/flexion of the knee joint and yielded a significantly worse result for the donor side than for the contralateral side.<sup>23</sup>

Musculoskeletal dysfunction is caused not only by direct injury to the vastus lateralis muscle, but also by injury to the motor nerve of the vastus lateralis muscle during harvesting of the ALT flap.<sup>7,13,15,17,22</sup> Only three anatomical studies have investigated the relationship between the lateral femoral circumflex artery and the motor nerve of the vastus lateralis muscle.<sup>13–15</sup> Casey et al reported the running pattern of the descending branch of the lateral femoral circumflex artery and motor nerve of the vastus lateralis muscle from clinical cases to assess injury rates.<sup>13</sup> Rozen et al performed anatomical studies on embalmed cadavers and examined the running patterns of the two largest perforators and the motor nerve of the vastus lateralis to assess injury rates.<sup>14</sup> Stewart et al reported the neurovascular anatomy at the “box junction,” the point at which the perforator arose from the source vessel.<sup>15</sup> However, the overall anatomy of these two were not assessed in previous studies, and their detailed anatomical relationship is still unclear. This study aimed to investigate the overall anatomic locations of the perforators from the descending branch of the lateral femoral circumflex artery and the motor nerve branches of the vastus lateralis muscle using fresh-frozen cadaveric specimens and to determine which branches of the motor nerve are at a higher risk of injury.

## MATERIALS AND METHODS

This study was conducted on 43 limbs from 23 fresh-frozen cadavers without surgical or trauma scars on the femur and was completed at the department of anatomy, faculty of medicine, Chiang-Mai University, with institutional ethical approval obtained.

### Dissection Technique

After inserting a 14 G needle into the femoral artery and ligating the proximal part of the puncture site, 30 mL of a silicone rubber compound (MICROFIL; Flow Tech Inc., Carver, USA. Compound: 12 mL, Diluent: 15 mL, and Curing agent: 3 mL) was injected into the femoral artery to visualize the vessels. One hour after the injection of the sclerosing agent, meticulous dissection under a 2.5 × surgical loupe was performed to expose all perforators from the descending branch of the lateral femoral circumflex artery and the motor nerves of the vastus lateralis muscle. Perforators from the transverse branch of the lateral femoral circumflex artery and the deep femoral artery were excluded.

We determined the reference line (AP line) from the anterior superior iliac spine to the top of the lateral border of the patella and measured the number of skin perforators from the descending branch of the lateral femoral circumflex artery and their locations through the fascia femoris, the number of branches from the motor nerve

## Takeaways

**Question:** What are the anatomical relations of the perforators and the motor nerve branches when anterolateral thigh flap is harvested.

**Findings:** This study was performed using 43 fresh-frozen cadaveric limbs. When the two most proximal perforators were used for flap harvesting, 42% of motor nerve branches were damaged.

**Meaning:** This study aimed to investigate the overall anatomic locations of the perforators and the motor nerve branches and to determine which branches of the motor nerve are at a higher risk of injury.

of the vastus lateralis muscle, and the locations where the motor nerve branches invaded the vastus lateralis muscle (motor points). The locations were expressed as 0%–100% from the proximal to the distal side of the AP line.

### Statistical Analysis

Statistical analyses were performed using SPSS for Windows, version 26.0 (IBM Corp., Armonk, N.Y.). The Mann–Whitney U test was used to compare the obtained data of locations of the perforators and the motor nerve branches. Statistical significance was set at *P* less than 0.05.

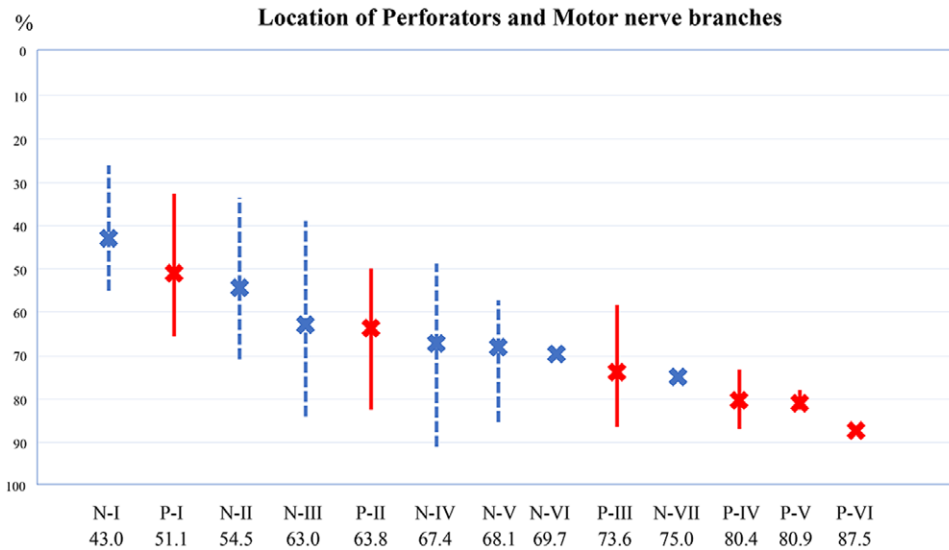
## RESULTS

The cadavers included 31 male and 12 female limbs of various shapes. The age at death ranged from 42 to 95 years (mean, 73.6 years), and height ranged from 142 to 175 cm (mean, 162.8 cm). The distance from the anterior superior iliac spine to the top of the lateral border of the patella was 38–46 cm (mean, 41.8 cm). There were one to six (mean, 2.7) skin perforators (Ps) from the descending branch of the lateral femoral circumflex artery. Ps were designated as P-I to P-VI from proximal to distal, respectively. There were two to seven (mean, four) branches of the motor nerve of the vastus lateralis muscle (Ns). Ns were designated as N-I to N-VII, from proximal to distal, respectively. **Table 1** show the rates of presence of the perforators and the nerve branches. **Figure 1** shows their mean locations.

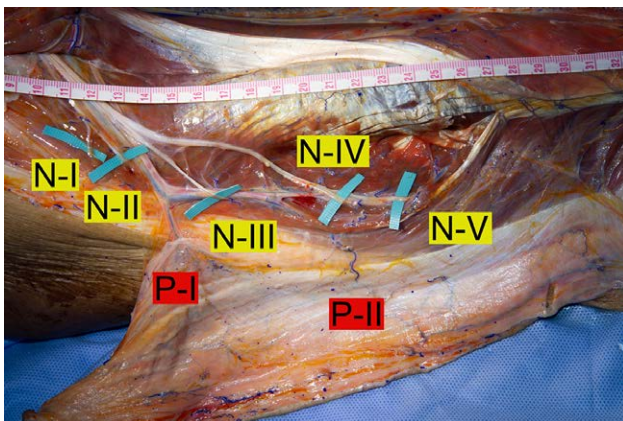
Comparing the locations between the perforators and the nerve branches, N-I and N-II were significantly more proximal than P-I (P-I/N-I: *P* < 0.01) and P-II (P-II/N-II:

**Table 1. Number and Presence Rate of Perforators from the Descending Branch of the Lateral Femoral Circumflex Artery and Motor Nerve Branches of the Vastus Lateralis Muscle**

	Perforators, No. (%)	Motor Nerve Branches, No. (%)
I	43 (100)	43 (100)
II	40 (93)	43 (100)
III	21 (49)	41 (95)
IV	10 (23)	17 (40)
V	3 (7)	8 (19)
VI	1 (2)	2 (5)
VII		1 (2)



**Fig. 1.** Graph showing the locations of the perforators and motor nerve branches. The average locations of the perforators through the femoral fascia are as follows: P-I: 51.1%, P-II: 63.8%, P-III: 73.6%, P-IV: 80.4%, P-V: 80.9% P-VI: 87.5%. The mean locations of the motor nerve points are as follows: N-I: 43.0%, N-II: 54.5%, N-III: 63.0%, N-IV: 67.4%, N-V: 68.1%, N-VI: 69.7%, and N-VII: 75.0%.



**Fig. 2.** A photograph of the flap harvesting with two perforators. When the two proximal perforators (P-I and P-II) are used for flap harvesting, two nerves (N-III and N-IV) are damaged.

$P < 0.01$ ), respectively. On the other hand, there were no significant differences between the distributions of P-I and N-II, P-II and N-III, P-II and N-IV, and P-II and N-V (P-I/N-II:  $P = 0.079$ , P-II/N-III:  $P = 0.985$ , P-II/N-IV:  $P = 0.329$ , P-II/N-V:  $P = 0.438$ ). When the two most proximal perforators (P-I and P-II) were used for flap harvesting from 40 limbs with two or more perforators, 60 nerve branches (N-I: 9, N-II: 26, N-III: 17, N-IV: 6, and N-V: 2) from 144 (42%) between the two perforators were damaged because transection of the motor nerve branches was required for flap harvesting (Fig. 2). On average, this was equivalent to damaging 1.5 motor nerve branches per limb. In 13 of the 40 limbs (33%), only one motor nerve branch (N-I: 8, N-II: 2, N-III: 1, N-IV: 1, and N-V: 1) remained after transection of the motor nerve branches during flap harvesting. However, there were no cases where all motor nerve

branches were severed. When the three most proximal perforators (P-I, P-II, and P-III) were used from 21 limbs with three or more perforators for flap harvesting, 39 nerve branches (N-I: 7, N-II: 17, N-III: 12, N-IV: 2, and N-V: 1) from the total of 67 nerves (58%) could be damaged. In 13 of the 21 limbs (62%), only one motor nerve branch (N-I: 7, N-II: 3, and N-III: 3) remained after transection of the motor nerve branches during flap harvesting. There was one case where all motor nerve branches were severed.

### DISCUSSION

The results of this study showed that there was an average of 2.7 perforators from the lateral femoral circumflex artery, and 93% of the cadavers had at least two perforators that could be used for ALT flap harvesting. The average locations of these two perforators (P-I and P-II) were 51.1% and 63.8%, respectively, on the reference line from the anterior superior iliac spine to the top of the lateral border of the patella. The number and distribution of the perforators were similar to those reported in previous studies.<sup>9,24</sup>

In contrast, the number of motor nerve branches of the vastus lateralis muscle ranged from two to seven (mean, four), and 95% of the cadavers had at least three motor nerve branches. The average locations of the three motor nerve branches (N-I, N-II, and N-III) on the AP line were 43.0%, 54.5%, and 63.0%, respectively. Statistically, the most proximal motor branch (N-I) was located more proximally than the most proximal perforator (P-I), which might indicate that the N-I was unlikely to be injured during flap harvesting. However, N-II was located between P-I and P-II, which might indicate that N-II was most likely injured during flap harvesting when both P-I and P-II were included in the flap. Statistically, there were no significant differences in the locations between N-III and P-II, N-IV

and P-II, and N-V and P-II, which might indicate that there was a potential risk of injury to N-III, N-IV, and N-V during flap harvesting.

When the two most proximal perforators (P-I and P-II) were used for flap harvesting, 42% of the motor nerve branches located between P-I and P-II were damaged. However, there were no cases in which all motor nerve branches were severed. These results support previous reports that the ALT flap containing two perforators does not cause severe muscle weakness at the donor-site,<sup>17,19,20,22,23</sup> because the risk of sacrificing all motor nerves is very low. However, when the three most proximal perforators (P-I, P-II, and P-III) were used for flap harvesting, 58% of the motor nerve branches were damaged, and there was one case that killed all the motor nerve branches. As expected, the risk of nerve damage was found to increase with using more perforators for flap harvesting.

The vastus lateralis muscle is innervated by several motor nerve branches, and it is still unclear how many sacrificing branches will cause clinically significant dysfunction.<sup>14</sup> The results of our study indicate that limbs with a small number of the motor nerve branches are likely to leave only one nerve branch after the flap harvest if two perforators are included in the flap (Fig. 3). In such cases, muscle weakness occurs more readily. However, despite the possibility of such cases, it is difficult to identify all nerve branches intraoperatively. To prevent muscle weakness, it may be preferable to repair the severed nerve as much as possible after flap harvesting, or to abandon the use of two perforators when a single perforator is enough to nourish a flap.

Our study revealed that 42% of the motor nerve branches between the two perforators could be damaged during flap harvesting. A retrospective study by Casey et al<sup>13</sup> described that the motor nerve of the vastus lateralis muscle runs in three patterns around the descending branch of the lateral femoral circumflex artery in 43 clinical ALT flap cases, and the motor nerve could be damaged in 7% of cases when harvesting

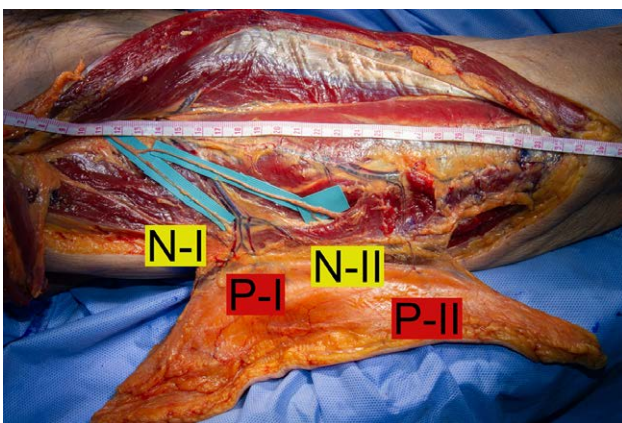
the flap because it passed over the perforators. They reported that to save the motor nerve, the donor-site was changed to the opposite side in one case, the ALT flap was changed to a tensor fasciae latae flap in one case, and nerve suturing was performed after resection in one case. Rozen et al<sup>14</sup> reported on 36 embalmed cadavers dissected to study the running pattern of the two largest perforators and the motor nerve of the vastus lateralis muscle. They reported three unfavorable motor nerve running patterns: the motor nerve passing through the perforator, through the main descending branch, or between the two perforators, with 10 of 36 specimens (28%) having the potential for injury. Most recently, Stewart et al<sup>15</sup> reported on 20 embalmed cadavers to investigate the “box junction” that was defined as the circle of 10 mm radius centered on the point at which the perforator arose from the source vessel. The motor nerve branches were commonly related to perforators with most box junctions (45%) containing one or more branches of the nerve. They also found that 24% of perforators had potential to affect flap harvest because of involving the nerve crossing directly over the perforator at the box junction.

Compared with previous studies, our reported injury rate was higher (42%). The reason for this higher injury rate may be explained as follows: Casey et al conducted a retrospective clinical study.<sup>13</sup> They did not observe the entire anatomy of the descending branches of the lateral femoral circumflex artery or the motor nerve branches of the vastus lateralis muscle during surgery. Only the running patterns of the main trunk of the motor nerve of the vastus lateralis muscle were investigated, and not all branches, as in our study. Rozen et al identified the two largest perforators and investigated their relationship with the motor nerve of the vastus lateralis muscle.<sup>14</sup> They used embalmed specimens with limited investigation and did not identify all the perforators, as in our study. Stewart et al also used embalmed cadavers.<sup>15</sup> They investigated only the point of intersection between the perforators and the source vessel, and not all branches, as in our study. In our study, more detailed anatomical studies could be performed by using fresh-frozen cadaveric limbs with injection of Microfil to visualize the tiny vessels. Small perforators and motor nerve branches were identified more clearly than in previous studies, which may have resulted in a higher injury rate.

Our study had some limitations. First, the results using cadavers may differ from those of living bodies; the clinical detriment of sacrificing a few motor nerve branches has not been determined, and the need for repair of the damaged nerve branches is unknown. Second, we did not mention the size of perforators and branches of the motor nerve. The larger nerve branches might be more functionally important, but it was difficult to prove this in anatomical study.

## CONCLUSIONS

This anatomical study revealed that 42% of the motor nerve branches of the vastus lateralis muscle were damaged



**Fig. 3.** A photograph of the flap harvesting with two perforators in a limb with a small number of motor nerve branches. When the two proximal perforators (P-I and P-II) are used for flap harvesting, one nerve (N-II) is damaged, and only N-I remains.

when two perforators were included in the ALT flap. In 33% of the limbs, only one motor nerve branch remained after flap harvesting. These results highlight the importance of considering specific measures such as repairing severed nerves and reconsidering the use of two perforators.

**Kenji Kawamura, MD**

Department of Orthopaedic Surgery  
Nara Medical University  
840 Shijyo-cho, Kashihara  
Nara 634-8522, Japan  
E-mail: kkenji@naramed-u.ac.jp

#### DISCLOSURE

*The authors have no financial interest to declare in relation to the content of this article.*

#### REFERENCES

- Song YG, Chen GZ, Song YL. The free thigh flap: a new free flap concept based on the septocutaneous artery. *Br J Plast Surg*. 1984;37:149–159.
- Koshima I, Fukuda H, Yamamoto H, et al. Free anterolateral thigh flaps for reconstruction of head and neck defects. *Plast Reconstr Surg*. 1993;92:421–428; discussion 429.
- Kimura N, Satoh K. Consideration of a thin flap as an entity and clinical applications of the thin anterolateral thigh flap. *Plast Reconstr Surg*. 1996;97:985–992.
- Chana JS, Wei FC. A review of the advantages of the anterolateral thigh flap in head and neck reconstruction. *Br J Plast Surg*. 2004;57:603–609.
- Chen CM, Chen CH, Lai CS, et al. Anterolateral thigh flaps for reconstruction of head and neck defects. *J Oral Maxillofac Surg*. 2005;63:948–952.
- Luenam S, Prugsawan K, Kosiyatrakul A, et al. Neural anatomy of the anterolateral thigh flap. *J Hand Microsurg*. 2015;7:49–54.
- Revenaugh PC, Knott D, McBride JM, et al. Motor nerve to the vastus lateralis. *Arch Facial Plast Surg*. 2012;14:365–368.
- Koshima I, Fukuda H, Utunomiya R, et al. The anterolateral thigh flap; variations in its vascular pedicle. *Br J Plast Surg*. 1989;42:260–262.
- Kimata Y, Uchiyama K, Ebihara S, et al. Anatomic variations and technical problems of the anterolateral thigh flap: a report of 74 cases. *Plast Reconstr Surg*. 1998;102:1517–1523.
- Goel S, Arora J, Mehta V, et al. Unusual disposition of lateral circumflex femoral artery: anatomical description and clinical implications. *World J Clin Cases*. 2015;3:85–88.
- Patil S, Grigoris P, Shaw-Dunn J, et al. Innervation of vastus lateralis muscle. *Clin Anat*. 2007;20:556–559.
- Page BJ, Mrowczynski OD, Payne RA, et al. The relative location of the major femoral nerve motor branches in the thigh. *Cureus*. 2019;11:e3882.
- Casey WJ III, Rebecca AM, Smith AA, et al. Vastus lateralis motor nerve can adversely affect anterolateral thigh flap harvest. *Plast Reconstr Surg*. 2007;120:196–201.
- Rozen WM, le Roux CM, Ashton MW, et al. The unfavorable anatomy of vastus lateralis motor nerves: a cause of donor-site morbidity after anterolateral thigh flap harvest. *Plast Reconstr Surg*. 2009;123:1505–1509.
- Stewart M, Brassett C, Abood A. Neurovascular anatomy at the “box junction”: considerations in the anterolateral thigh flap. *J Reconstr Microsurg*. 2019;35:254–262.
- Kimata Y, Uchiyama K, Ebihara S, et al. Anterolateral thigh flap donor-site complications and morbidity. *Plast Reconstr Surg*. 2000;106:584–589.
- Kuo YR, Jeng SF, Kuo MH, et al. Free anterolateral thigh flap for extremity reconstruction: clinical experience and functional assessment of donor site. *Plast Reconstr Surg*. 2001;107:1766–1771.
- Lipa JE, Novak CB, Binhammer PA. Patient-reported donor-site morbidity following anterolateral thigh free flaps. *J Reconstr Microsurg*. 2005;21:365–370.
- Tsuji N, Suga H, Uda K, et al. Functional evaluation of anterolateral thigh flap donor sites: isokinetic torque comparisons for knee function. *Microsurgery*. 2008;28:233–237.
- Hanasono MM, Skoracki RJ, Yu P. A prospective study of donor-site morbidity after anterolateral thigh fasciocutaneous and myocutaneous free flap harvest in 220 patients. *Plast Reconstr Surg*. 2010;125:209–214.
- Collins J, Ayeni O, Thoma A. A systematic review of anterolateral thigh flap donor site morbidity. *Can J Plast Surg*. 2012;20:17–23.
- Agostini T, Lazzeri D, Spinelli G. Anterolateral thigh flap: systematic literature review of specific donor-site complications and their management. *J Craniomaxillofac Surg*. 2013;41:15–21.
- Weise H, Naros A, Blumenstock G, et al. Donor site morbidity of the anterolateral thigh flap. *J Craniomaxillofac Surg*. 2017;45:2105–2108.
- Iida H, Ohashi I, Kishimoto S, et al. Preoperative assessment of anterolateral thigh flap cutaneous perforators by colour Doppler flowmetry. *Br J Plast Surg*. 2003;56:21–25.