

SIGMOID SEPTUM CAUSING AORTIC REGURGITATION : A CASE REPORT

REIKO MIZUNO and KAZUHIRO DOHI

First Department of Internal Medicine, Nara Medical University

SHINICHI FUJIMOTO and HIROSHI NAKANO

Department of Clinico-Laboratory Diagnostics, Nara Medical University

Received June 22, 1998

Abstract : An 86-year-old woman with a sigmoid septum that caused aortic regurgitation (AR) is described. The patient visited our hospital because of dyspnea and leg edema. On auscultation, a characteristic Levine 3/6 diastolic musical murmur was heard in Erb's area. A 12-lead electrocardiogram showed atrial fibrillation (heart rate=68/min) but no evidence of ischemic change. Chest radiography showed cardiomegaly but no pulmonary congestion. Two-dimensional echocardiography revealed a basal interventricular septum (IVS) markedly protruding into the left ventricular outflow tract (sigmoid septum). The angle formed by the aorta and the IVS (aorto-septal angle) was about 70 degrees. Furthermore, prolapse of the right coronary cusp toward the left ventricle accompanied by paradoxical motion of the basal IVS during diastole was also observed. Color Doppler echocardiography detected a localized and distinct regurgitant jet flow from the right coronary cusp toward the base of the anterior mitral leaflet. According to Seller's classification, the AR was grade 2. These findings suggest that AR may develop in patients with a sigmoid septum due to prolapse of the right coronary cusp leading to paradoxical motion of the basal IVS. (奈医誌. J. Nara Med. Ass. 49, 288~292, 1998)

Key words : aortic regurgitation, color Doppler echocardiography, sigmoid septum

INTRODUCTION

A marked protrusion of the interventricular septum (IVS) into the left ventricular (LV) cavity, so-called sigmoid septum, has been reported to be an exaggeration of the physiological bending of the IVS and to be caused by the physiological decrease in cardiac output associated with aging and shrinking of the LV cavity¹⁾. Although a sigmoid septum is not considered to be of any clinical significance¹⁾, recent noninvasive studies have demonstrated that LV outflow tract obstruction may develop in some patients with a sigmoid septum²⁾, occasionally provoking a high-pressure gradient across the LV outflow tract³⁾. In the present report, we describe an interesting case of a sigmoid septum causing aortic regurgitation (AR) and discuss the mechanism of this phenomenon.

CASE REPORT

An 86-year-old woman visited our hospital because of dyspnea and leg edema in February 1997. There was no significant evidence of heart disease in her past history or family history. She had been under medical care for hypertension elsewhere since 1985. She had suffered from

dyspnea on exertion and leg edema since January 1997. Her symptoms worsened gradually, so she visited our hospital. On examination, her height was 152 cm and weight 46 kg. Blood pressure was 170/90 mmHg and heart rate was 68/min with an irregular rhythm. A characteristic Levine 3/6 diastolic musical murmur, which was loudest in Erb's area, was heard. There was peripheral edema in the lower extremities, but no digital clubbing or cyanosis. Inspiratory crackles suggesting congestive heart failure were not heard. The abdominal and neurological

Table 1. Laboratory data on admission

Urinalysis		ESR		BUN	25 mg/dl
Sugar	(-)	12 mm/1hr		UA	8.0 mg/dl
Protein	(1+)			Na	142 mEq/l
Occult blood	(-)	Blood biochemistry		K	4.3 mEq/l
		GOT	32 IU/l	Cl	106 mEq/l
Hematology		GPT	21 IU/l	Ca	9.2 mg/dl
RBC	405 × 10 ⁴ /μl	ALP	183 IU/l	Serology	
Hb	12.4 g/dl	TP	6.3 g/dl	CRP	0.1 mg/dl
Ht	36.9 %	Alb	4.1 g/dl	ASO	35 Todd
WBC	6,000 /μl	TC	138 mg/dl	hANP	88.5 pg/ml
Plt	25.3万 /μl	Scr	2.0 mg/dl		

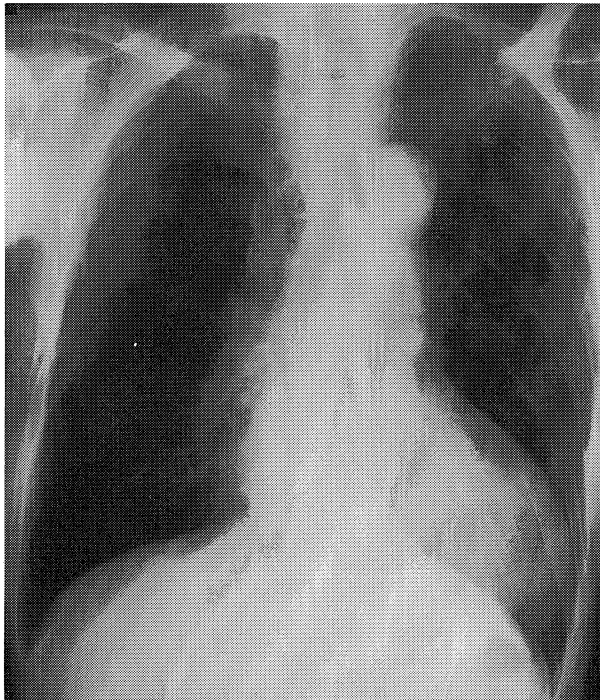

Fig. 1. Chest radiography on admission. The chest radiography showed cardiomegaly (cardiothoracic ratio=60%), but no pulmonary edema.

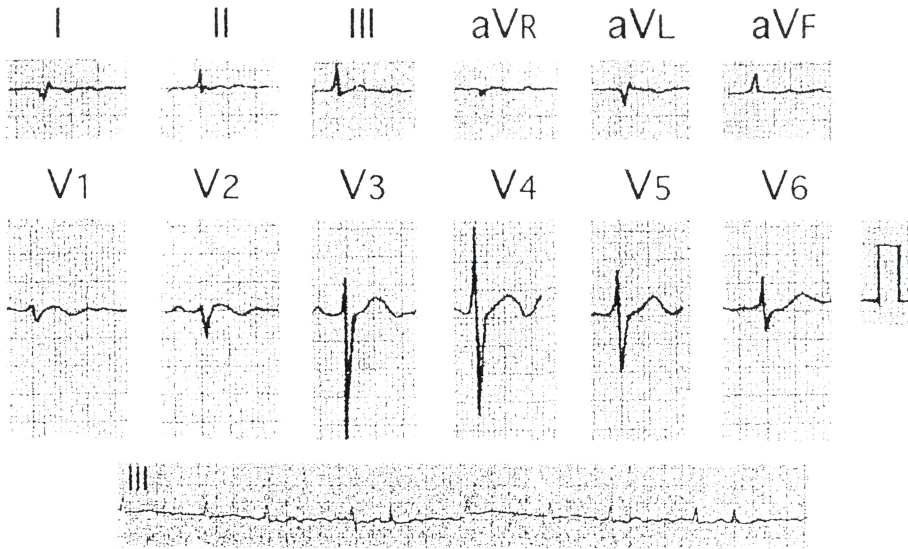


Fig. 2. Electrocardiogram on admission. The electrocardiogram showed atrial fibrillation (heart rate \approx 70/min), but no significant evidence of ischemic change.

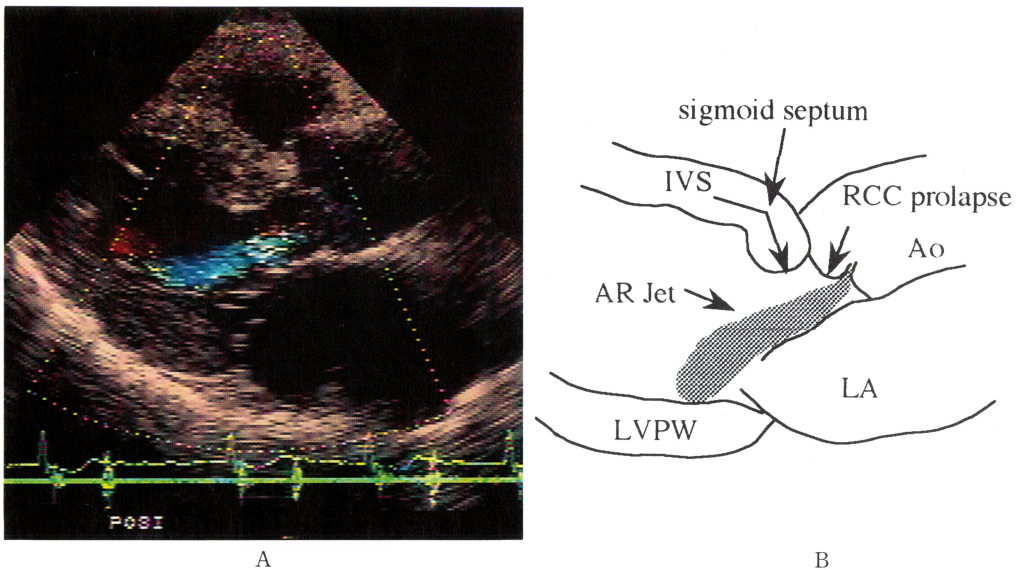


Fig. 3. Two-dimensional echocardiography (A) and schema showing the mechanism of aortic regurgitation in a sigmoid septum (B).

A marked protrusion of the basal portion of the interventricular septum and a prolapse of the right coronary cusp towards the left ventricle, further a localized regurgitant jet flow from the right coronary cusp were seen in a diastole frame. IVS; interventricular septum, LV; left ventricle, LVPW; left ventricular posterior wall, Ao; aorta, LA; left atrium, RCC; right coronary cusp, AR; aortic regurgitation.

findings revealed no significant abnormalities.

The laboratory examination showed proteinuria (1+) and elevation of serum blood urea nitrogen, creatinine, glutamic oxaloacetic transaminase, and atrial natriuretic peptide (Table 1). Chest radiography showed cardiomegaly (cardiothoracic ratio=60 %) but no pulmonary edema (Fig. 1). An electrocardiogram showed atrial fibrillation (heart rate \approx 70/min), but no significant evidence of ischemic change (Fig. 2). A two-dimensional echocardiogram revealed a basal interventricular septum (IVS) markedly protruding into left ventricular outflow tract, or a so-called sigmoid septum. The angle formed by the aorta and the IVS (aorto-septal angle) was about 70 degrees. Furthermore, prolapse of the right coronary cusp toward the left ventricle accompanied by paradoxical motion of the basal IVS during diastole was also observed, but no abnormal echo suggesting vegetation was recognized on the cusps. M-mode echocardiographic measurement disclosed that the thickness of the IVS and LV posterior wall 1.8 cm and 1.3 cm, respectively, LV end-diastolic dimension 4.9 cm, LV end-systolic dimension 3.0 cm, left atrial dimension 5.0 cm, aortic root dimension 3.3 cm, and fractional shortening 38.8 %. Systolic anterior motion of the mitral valve (SAM) was not demonstrated. Color Doppler echocardiography detected a localized and distinct regurgitant jet flow from the right coronary cusp toward the base of the anterior mitral leaflet. According to Seller's classification, the AR was grade 2 (Fig. 3).

DISCUSSION

1. The mechanism underlying aortic regurgitation in a sigmoid septum

A sigmoid septum has been reported to be an exaggeration of the physiologic process of aging. Sclerotic and fibrous changes in the aorta and IVS were suggested as causes of a sigmoid septum⁴. A sigmoid septum has been believed to have little pathophysiological or clinical significance. However, a recent noninvasive study revealed that LV outflow obstruction might develop in some patients with a sigmoid septum². In that study, the obstruction was ascribed to a sigmoid septum, narrowed LV and LV hyperkinetic motion associated with systolic anterior motion of the mitral valve (SAM)².

In the present case, a sigmoid septum with AR was observed and it appeared that paradoxical motion of the IVS caused by a sigmoid septum was related to the development of AR.

A schema showing the proposed mechanism occurring aortic regurgitation associated with a sigmoid septum is shown in Fig. 3. The schema shows the parasternal long axis view of the LV in diastole. In diastole, the IVS moves toward the aortic root as a whole in normal subjects, while the basal portion of the IVS is pulled toward the apex of LV in patients with sigmoid septum, although the apical portion of IVS moves toward the aorta as in normal subjects. As a result, it is thought that AR may develop because of prolapse of the right coronary cusp toward LV.

2. Aortic regurgitation associated with hypertrophic cardiomyopathy

Shiota T et al described AR associated with hypertrophic cardiomyopathy (HCM)⁵. In that report, mild AR was found in almost a quarter of patients with HCM. There were no significant differences between patients of HCM with and without AR in terms of age, blood pressure, aortic diameter, or frequency of calcification of the aortic valve and SAM. On cross-sectional echocardiography, the degree of IVS protrusion into the LV outflow tract was

significantly more prominent, and the portion of the basal IVS that protruded most deeply into the LV outflow tract was significantly closer to the aortic annulus in patients with AR than in those without it. Therefore, it was thought that AR in patients with HCM was related to the morphological abnormalities of the LV outflow tract. In addition, Frank and Braunwald reported that seven of 126 patients with idiopathic HCM had diastolic murmurs that were best heard at the apex in all seven⁶⁾. Barlow and Pocock suggested that morphological abnormalities, that is, distortion of the aortic annulus caused by asymmetric myocardial hypertrophy, may result in AR⁷⁾. This mechanism of AR occurring in patients with HCM appears to closely resemble that in the present case. Thus, a sigmoid septum should not be underestimated as a physiological phenomenon associated with aging; furthermore its significance as a clinical entity should be investigated.

REFERENCES

- 1) **Goor, D., Lillehei, C. W. and Edwards, J. E.** : The "sigmoid septum". Variation in the contour of the left ventricular outlet. *Am. J. Roentgenol.* **107** : 366-374, 1969.
- 2) **Fukuda, N., Asai, M., Tomonaga, T., Irahara, K., Mikawa, T., Yamamoto, M., Ohshima, C., Kusaka, Y., Oki, T., Niki, T. and Mori, H.** : Noninvasive studies of dynamic left ventricular outflow obstruction in patients with sigmoid septum. *J. Cardiology.* **14** : 445-452, 1984.
- 3) **Kimura, A., Fujimoto, S., Mizuno, R., Nakano, H., Shirai, T. and Dohi, K.** : A case of sigmoid septum with significantly high left ventricular outflow pressure gradient. *J. Nara Med. Ass.* **49** : 123-126, 1998.
- 4) **Nishida, K., Saito, T., Kamijima, G., Honda, M., Yanagisawa, N., Higuchi, Y. and Wada, T.** : Echocardiographic findings of the "sigmoid septum" and its clinical implication. *J. Cardiology.* **10** : 873-881, 1980.
- 5) **Shiota, T., Sakamoto, T., Takenaka, K., Amano, K., Hada, Y., Hasegawa, I., Suzuki, J., Takahashi, H. and Sugimoto, T.** : Aortic regurgitation associated with hypertrophic cardiomyopathy : a colour Doppler echocardiographic study. *Br. Heart. J.* **62** : 171-176, 1989.
- 6) **Frank, S. and Braunwald, E.** : Idiopathic hypertrophic subaortic stenosis. Clinical analysis of 126 patients with emphasis on the natural history. *Circulation.* **37** : 759-788, 1968.
- 7) **Barlow, J. B. and Pocock, W. A.** : Hypertrophic cardiomegaly. In Barlow, I. B., ed. *Perspectives on the mitral valve : conditions involving the mitral valve mechanism.* Philadelphia : FA Davis. : 198-211, 1987.